

Pregnancy-Related Tuberculous Meningitis and Immune Reconstitution Inflammatory Syndrome: A Case Series and Systematic Review

Katelyn A. Pastick,^{1,2,3} Enoch Kagimu,^{3,4} Joanna Dobbin,^{4,5} Kenneth Ssebambulidde,^{3,6} Jane Gakuru,^{3,6} Jack Milln,^{5,6,7} Betty Nakabuye,^{7,8,9} David B. Meya,^{3,9} David R. Boulware,^{2,10} Fiona V. Cresswell,^{6,9,10} and Nathan C. Bahr^{10,11}

¹Department of Medicine, Massachusetts General Hospital, Boston, Massachusetts, USA, ²Department of Medicine, University of Minnesota, Minneapolis, Minnesota, USA, ³Infectious Diseases Institute, Makerere University, Kampala, Uganda, ⁴Primary Care and Population Health, University College London, London, United Kingdom, ⁵Department of Obstetric Medicine, Queen Charlotte's and Chelsea Hospital, London, United Kingdom, ⁶Medical Research Council/Uganda Virus Research Institute and London School of Hygiene and Tropical Medicine Uganda Research Unit, Entebbe, Uganda, ⁷Department of Obstetrics and Gynecology, Uganda Martyrs Hospital Lubaga, Kampala, Uganda, ⁸School of Public Health, Makerere University College of Health Sciences, Kampala, Uganda, ⁹Global Health and Infection, Brighton and Sussex Medical School, Brighton, United Kingdom, and ¹⁰Division of Infectious Diseases, Department of Medicine, University of Kansas Medical Center, Kansas City, Kansas, USA

Background. Tuberculosis is a leading cause of death among women of reproductive age. However, tuberculous meningitis, the most severe form of extrapulmonary tuberculosis, is rarely discussed in pregnancy despite this being a unique period of immune modulation that may predispose women to active disease.

Methods. We identified and described cases of tuberculous meningitis among pregnant or postpartum women screened during meningitis clinical trials in Uganda from 2018 to 2022. We conducted a systematic literature review via PubMed/Medline and Embase for all English-language publications from 1970 to 10 July 2022, to identify additional cases.

Results. We identified 8 cases of pregnancy-related tuberculous meningitis in Ugandan women living with human immunodeficiency virus (HIV) and 40 additional cases via systematic literature review (none HIV-positive). Of all combined cases, 50% (24/48) were diagnosed postpartum; 50% (24/48) had initial onset during pregnancy, of which 38% (9/24) had worsening of symptoms or disease relapse following pregnancy cessation. Diagnosis was missed or delayed in 33% (16/48) of cases. For those with known outcomes, maternal mortality was 23% (11/48) and fetal/neonatal mortality was 30% (13/44). Of maternal survivors, 30% (11/37) had residual neurologic deficits.

Conclusions. The true incidence of tuberculous meningitis in pregnancy or the postpartum period is unclear but likely underappreciated. To date, nearly all published cases have occurred in HIV-negative or otherwise immunocompetent women. Given the well-described physiological immunosuppression during pregnancy and subsequent reconstitution postpartum, physicians must be aware of tuberculous meningitis and pregnancy-related immune reconstitution inflammatory syndrome, especially in countries with a high burden of tuberculosis and in women living with HIV.

Keywords. HIV/AIDS; immune reconstitution; meningitis; postpartum; pregnancy; tuberculosis.

Tuberculosis (TB) is one of the leading causes of death among women of reproductive age and is associated with preterm birth, intrauterine growth restriction, subsequent low birth weight, and a 6-fold increase in perinatal death [1]. Tuberculous meningitis (TB meningitis) accounts for 1%–2% of TB cases in individuals without human immunodeficiency

virus (HIV), 4%–7% of all TB cases in people living with HIV, and around 15%–20% of HIV-associated meningitis diagnoses [2]. Late presentation and delayed diagnosis are key contributors to a high mortality rate (~30% overall) [2]. The exact incidence of TB meningitis in pregnant women is unknown; however, 10%–50% of participants in published TB meningitis cohorts were women of reproductive age [3–7].

Pregnancy is a period of systemic immune modulation with a complex balance of immunosuppression to prevent rejection of the fetus and maintenance of the ability to fight off infections. Specific immunologic changes in pregnancy include an up-regulation of regulatory T cells and a switch from type 1 T-helper (Th1) cells and proinflammatory cytokines (eg, interleukin [IL]–12, interferon- γ , tumor necrosis factor [TNF]- α) to type 2 T-helper (Th2) (eg, IL-10) and type 3 T-helper (eg, TNF- β) cytokines, resulting in reduced cell-mediated immunity [8, 9]. These changes rapidly reverse following delivery with

Received 15 July 2022; editorial decision 28 September 2022; accepted 03 October 2022; published online 6 October 2022

Correspondence: Katelyn A. Pastick, MD, Massachusetts General Hospital, Department of Medicine, 55 Fruit St, Boston, MA 02114 (kpastick@mgh.harvard.edu).

Open Forum Infectious Diseases®

© The Author(s) 2022. Published by Oxford University Press on behalf of Infectious Diseases Society of America. This is an Open Access article distributed under the terms of the Creative Commons Attribution-NonCommercial-NoDerivs licence (<https://creativecommons.org/licenses/by-nc-nd/4.0/>), which permits non-commercial reproduction and distribution of the work, in any medium, provided the original work is not altered or transformed in any way, and that the work is properly cited. For commercial re-use, please contact journals.permissions@oup.com

<https://doi.org/10.1093/ofid/ofac513>

immune reconstitution, resulting in postpartum flares of rheumatologic or infectious diseases [8, 10, 11]. Importantly, Th2-predominant immune responses are associated with progression and severity of TB disease [12, 13]. These changes may ultimately increase the risk for TB (including TB meningitis) in pregnancy, and rapid postpartum immune reconstitution may contribute to worsening of TB symptoms and increase in postpartum diagnoses [14–16].

Immune reconstitution inflammatory syndrome (IRIS) in people living with HIV may describe the worsening or unmasking of a subclinical disease following antiretroviral therapy (ART) initiation (ie, unmasking IRIS) or symptom recurrence in a partially treated infection following ART initiation (ie, paradoxical IRIS) [17]. In HIV-associated TB meningitis, IRIS most frequently occurs 2–4 weeks after starting ART but can occur up to 3 months later and may occur in up to 50% of cases [17]. Importantly, paradoxical IRIS and similar reactions can affect HIV-negative persons following reversal of immunosuppressive conditions, such as cessation of pregnancy, medications, or start of TB therapy [18]. Cases of IRIS associated with pregnancy have been reported in HIV-positive women with Kaposi sarcoma [19, 20], toxoplasmosis [21], cryptococcosis [22–27], and in HIV-negative women with TB meningitis [28]. Yet to our knowledge, there have been no descriptions of pregnancy-related TB meningitis IRIS in women living with HIV to date. We describe the first 8 cases of HIV-associated TB meningitis in pregnancy and the postpartum period and report the findings of a systematic literature review evaluating overall outcomes.

METHODS

Case Series and Patient Consent Statement

From September 2018 to April 2022, persons with suspected meningitis were enrolled in 3 studies at Kiruddu National Referral Hospital in Kampala, Uganda. One cohort study focused on improving diagnostics and neurocognitive outcomes for those presenting with meningitis [29, 30]. The other 2 studies were phase 2 and 3 randomized controlled trials that compared high-dose rifampicin with standard-dose rifampicin [31, 32]. Institutional review board (IRB) approvals were obtained through the University of Minnesota, Mulago Hospital IRB and the London School of Hygiene and Tropical Medicine ethics committee; regulatory approval was obtained from the Uganda National Council of Science and Technology. All participants provided written informed consent prior to meningitis screening permitting collection of clinical outcomes. Pregnant and breastfeeding women were excluded from interventions but received diagnostic testing for TB meningitis and standard-of-care therapy.

Literature Review

A systematic literature review was conducted per the Preferred Reporting Items for Systematic Reviews and Meta-Analyses

(PRISMA) guidelines for reports of TB meningitis associated with pregnancy. We searched PubMed/Medline and Embase using the Medical Subject Heading (MeSH) keywords “tuberculosis, meningeal” and “pregnancy” or “postpartum” or “peripartum” in PubMed/Medline and “mening*,” “tubercul*,” and “pregnan*,” “postpartum,” or “peripartum” in Embase for English-language manuscripts from 1970 to 10 July 2022. K. A. P. reviewed all title/abstracts for relevance. Publications unrelated to cases of TB meningitis in pregnancy or the postpartum period were excluded. References from included manuscripts were then searched for additional cases.

In the systematic literature review, symptom duration was defined using the highest value if a range was given. A delay in TB meningitis diagnosis and treatment for purposes of this manuscript was defined as ≥ 1 week of classic meningeal symptoms (ie, headache, altered mental status, fever, and/or neck stiffness) following initial presentation or as identified by the original authors.

RESULTS

Case Series

Eight cases of TB meningitis associated with pregnancy were identified (Tables 1 and 2). One maternal death occurred; all fetuses survived to time of delivery with 1 pregnancy ongoing at time of publication. Long-term outcomes were unknown. CD4⁺ T-cell counts for cases 1–3 and 7–8 were unknown.

Case 1

A 29-year-old woman presented 1 month postpartum following spontaneous vaginal delivery with a 2-week history of headaches and fevers, 5 days of visual changes, and 3 days of altered mental status. She also had night sweats and weight loss. Examination showed meningism, nuchal rigidity, and a Glasgow Coma Scale (GCS) score of 14/15. She had been diagnosed with HIV 6 years prior but was no longer taking ART and had not been in HIV care for 4 years. Cerebrospinal fluid (CSF) obtained via lumbar puncture (LP) confirmed TB meningitis via GeneXpert MTB/RIF Ultra (Cepheid, Sunnyvale, California). Sadly, the patient died after 3 days of standard TB meningitis treatment of rifampicin, isoniazid, ethambutol, and pyrazinamide with dexamethasone.

Case 2

A 34-year-old woman presented 1 month postpartum after a spontaneous vaginal delivery with a 2-week history of reduced appetite and altered mental status. She was admitted to a psychiatric hospital initially diagnosed with postpartum psychosis and was treated with haloperidol. Following a positive HIV test, she was diagnosed with HIV-induced psychosis. She then developed a headache and dizziness with a decline in GCS score and was transferred to the national referral hospital where

Table 1. Systematic Review of Tuberculous Meningitis in Pregnancy and the Postpartum Period

First Author, Publication Year [Reference]	Case Number	Age, y	Pregnancy Status	Symptom Duration ^a	HIV and ART Status	Maternal Outcome	Fetal/Neonatal Outcome
Pastick (current case series)	1	29	Postpartum, 4 wk	14 d	Positive (unknown CD4), not on ART	Died	Alive to delivery
	2	34	Postpartum, 4 wk	14 d	Positive (unknown CD4), not on ART	Alive, neurologic deficits	Alive to delivery
	3	26	Postpartum, <1 wk	1 d	Positive (unknown CD4), not on ART	Alive, neurologic deficits	Alive to delivery
	4	29	Postpartum, 4 wk	24 d	Positive (CD4 122 cells/ μ L), recent diagnosis, on ART	Alive	Alive to delivery
	5	30	Postpartum, 6 wk	NA	Positive (CD4 81 cells/ μ L), recent ART switch	Alive	Alive to delivery
	6	25	Postpartum, 12 wk	60 d	Positive (CD4 93 cells/ μ L), recent diagnosis, on ART	Alive	Alive to delivery
	7	38	Postpartum, 8 wk	60–90 d	Positive (unknown CD4), not on ART	Alive	Alive to delivery
	8	28	28 wk		14 d	Positive (unknown CD4), on ART	Alive
Ye, 2019 [33]	1	32	5–26 wk	13 d	NA	Alive	Died
Namani, 2017 [34]	2	25	24 wk	>14 d	Negative	Alive	Died, twins
Nakatani, 2017 [35]	3	30	19 wk	14 d	Negative	Alive, neurologic deficits	Stillbirth, 23 wk
Baidya, 2011 [36]	4	26	>37 wk	14 d	NA	Alive	Alive, term delivery
Yeh, 2009 [37]	5	18	23 wk	21 d	Negative	Alive, neurologic deficits	Alive, delivered at 33 wk
Jana, 2008 [38]	6	25	10 wk	14–28 d	Negative	Alive, neurologic deficits	Died, intrauterine fetal death at 35 wk
Prevost, 1999 [39]	7	23	23 wk	7 d	Negative	Alive, neurologic deficits	Alive, delivered at 36 wk
Clark, 1986 [40]	8	19	24–26 wk	56 d	NA	Died	Alive, emergent cesarean delivery at 24–26 wk
Kingdom, 1989 [41]	9	23	28 wk	84 d	NA	Died, 6 d postpartum	Alive, delivered at 28 wk
	10	28	Postpartum, <1 wk	28 d	NA	Alive	Died, delivered at 28 wk
	11	25	Postpartum, 2 wk	56 d	NA	Alive, neurologic deficits	Died, delivered at 28 wk
	12	35	Recent miscarriage 3 wk prior	28 d	NA	Alive	Miscarriage at 12 wk
Ray, 1997 [42]	13	23	Postpartum, <1 wk	10.5 d	Negative	Died, day 15	Alive, born at term
Liu, 2008 [43]	14	29	14 wk	16 d	Negative	Alive, neurologic deficits	Elective termination
Kutlu, 2007 [44]	15	18	14 wk	NA	Negative	Alive	Alive, in utero
Chan, 2003 [45]	16	35	Postpartum, 4 wk	2 d	NA	Alive, neurologic deficits	Alive, congenital TB delivered at 29 wk
Cheng, 2003 [28]	17	35	Postpartum, 4 wk	NA	Negative	Alive, neurologic deficits	Alive, delivered at 29 wk
Heywood, 1999 [46]	18	NA	Postpartum, 20 wk	NA	NA	Died 5 mo postpartum	Alive
	19	NA	Pregnant, EGA not reported	NA	NA	Died	NA
Jana, 1999 [47]	20	NA	Pregnant, EGA not reported	NA	NA	Alive	NA
	21	NA	Pregnant	NA	NA	Alive	NA
Ogawa, 1987 [48]	22	NA	Postpartum, 6 wk to 5 mo	NA	Negative	At least 1 of 4 died	Two spontaneous abortions
	23	NA	Postpartum, 6 wk to 5 mo	NA	Negative
	24	NA	Postpartum, 6 wk to 5 mo	NA	Negative
	25	NA	Postpartum, 6 wk to 5 mo	NA	Negative
McIntyre, 1987 [49]	26	23	26–30 wk	39 d	NA	Died	Alive, delivered at 28 wk

Table 1. Continued

First Author, Publication Year [Reference]	Case Number	Age, y	Pregnancy Status	Symptom Duration ^a	HIV and ART Status	Maternal Outcome	Fetal/Neonatal Outcome
Stands, 1977 [50]	27	29	20 wk	21 d	NA	Alive	Alive
Petrini, 1983 [51]	28	32	Postpartum, 7 wk	NA	NA	Alive	Died (congenital TB), delivered at 38 wk
Brandstetter, 1980 [52]	29	24	Postpartum, <1 wk	5 d	NA	Alive	Alive, delivered at 39 wk
Chambers, 1975 [53]	30	26	Pregnant, EGA not reported	7 d	NA	Died, day 9	Alive
Gordon-Nesbitt, 1973 [54]	31	NA	Postpartum, 10 wk	NA	NA	Died, 10 wk postpartum	Alive, delivered at 39 wk, congenital TB
Golditch, 1971 [55]	32	34	19 wk	NA	NA	Alive	Alive, delivered at 36 wk
Romero-Imbroda, 2020 [56]	33	23	Postpartum, not reported	14 d	Negative	Alive	Alive
Saleh, 2013 [57]	34	27	Postpartum, 6 wk	21 d	Negative	Alive	Alive
Shibolet, 1979 [58]	35	21	16 wk	NA	NA	Died	Alive
Meyers, 1974 [59]	36	26	33 wk	NA	NA	Alive	Alive, delivered at 35 wk
Wilson, 1973 [60]	37	20	16 wk	NA	NA	Alive	Alive
Meregildo Rodriguez, 2020 [61]	38	44	Posttermination, 6 wk	21 d	Negative	Alive	Clandestine abortion 6 wk prior
Smitha, 2013 [62]	39	33	28 wk	NA	NA ^b	Alive	Alive, delivered preterm
Samson Ejiji, 2013 [63]	40	38	27 wk	84 d	Negative	Alive, neurologic deficits	Alive, in utero

Abbreviations: ART, antiretroviral therapy; EGA, estimated gestational age; HIV, human immunodeficiency virus; NA, not available or unspecified; TB, tuberculosis.

^aApproximate.

^bUnable to obtain full manuscript.

antibiotics were started. She later developed meningism and a cranial nerve VI palsy. An LP was performed on day 3 of hospitalization (day 21 of symptoms) with an opening pressure of 400 mm H₂O. Probable TB meningitis was putatively diagnosed given low CSF glucose (<1.1 mmol/L), elevated protein (147 mg/dL), and lymphocyte-predominant pleocytosis (total 275 cells/ μ L, 78% lymphocytes). The patient had a negative CSF cryptococcal antigen, GeneXpert MTB/RIF Ultra, acid-fast bacilli (AFB) stain, urine GeneXpert, and urine Alere lipoarabinomannan (LAM) (Alere, Waltham, Massachusetts). Head

computed tomography (CT) showed an acute basal ganglia infarct and hydrocephalus. The patient was started on standard TB meningitis therapy and was discharged on day 16 with significant residual neurological deficits.

Case 3

A 26-year-old woman living with HIV presented 5 days postpartum with fevers and altered mental status. She had been diagnosed with HIV and pulmonary TB 18 and 4 months prior to admission but was reportedly nonadherent to ART and the

Table 2. Cerebrospinal Fluid Results for 8 Cases of Human Immunodeficiency Virus and Pregnancy-Related Tuberculous Meningitis

CSF Parameters	Case 1	Case 2	Case 3	Case 4	Case 5	Case 6	Case 7	Case 8
Opening pressure, mm H ₂ O (normal <250)	NA	400	15	200	80	280	70	170
White blood cells, cells/ μ L	625 (83% lymphocytes)	275 (78% lymphocytes)	165 (85% lymphocytes)	310 (85% lymphocytes)	<5	<5	<5	635 (83% lymphocytes)
Protein, mg/dL	187	147	103	184	90	79	29	138
Glucose, mmol/L	NA	<1.1	<1.1	<1.1	45	Unknown	59	Low
Lactate, mmol/L	NA	12.3	NA	NA	2.2	Unknown	2.4	5.5
AFB stain	–	–	–	–	–	–	–	–
CSF GeneXpert MTB/RIF Ultra	+	–	+	+	–	+	–	–
Urine GeneXpert MTB/RIF Ultra	–	–	–	–	–	–	–	–
Urine LAM	–	–	–	–	+	+/- ^a	–	+
CSF culture	+	–	+	–	NA	NA	NA	NA

Abbreviations: –, negative; +, positive; AFB, acid-fast bacilli; CSF, cerebrospinal fluid; LAM, lipoarabinomannan; NA, not performed or not available.

^aPositive Fuji LAM, negative Alere LAM.

continuation phase of rifampicin and isoniazid. She was initially diagnosed with postpartum psychosis. During hospitalization, she developed neck pain, seizures, and cranial nerve VI–VII palsies and experienced a subsequent GCS decline. Antibiotics were started due to concern for retained placental tissue. She underwent an LP on day 21 of symptoms with an opening pressure of 15 mm H₂O and positive CSF GeneXpert MTB/RIF Ultra. She was started on standard TB meningitis therapy and phenytoin. The patient's consciousness level improved but right-sided hemiplegia persisted; she was discharged after 12 days of TB therapy.

Case 4

A 29-year-old woman became unwell following spontaneous vaginal delivery with nonspecific weakness, weight loss, and diaphoresis. She was found to be HIV positive with a CD4⁺ count of 122 cells/μL and was immediately started on ART. She continued to deteriorate and eventually presented to the hospital with a 24-day history of headache and 2–4 days of confusion and visual changes. She was cachexic and had nuchal rigidity, a cranial nerve VI palsy, and paraplegia with a GCS score of 14/15. CSF was obtained via LP with an opening pressure of 200 mm H₂O and was GeneXpert MTB/RIF Ultra positive. She was started on standard TB meningitis therapy and was discharged 17 days after admission.

Case 5

A 30-year-old woman living with HIV for >10 years recently switched ART due to a nonsuppressed HIV viral load on second-line ART and suboptimal adherence with a CD4⁺ count of 81 cells/μL. She was admitted to the hospital 6 weeks postpartum in status epilepticus with reports of high-grade fevers and a cough. Following resolution of seizures, she remained confused with severe meningism and a cranial nerve VII palsy. Serum and CSF cryptococcal antigen tests were negative. Her LP revealed an opening pressure of 80 mm H₂O and noninflammatory CSF, with a negative GeneXpert MTB/RIF Ultra, but positive urine Alere LAM (grade 4+). Her chest radiograph was consistent with miliary TB. She was treated for probable TB meningitis with standard therapy. After 14 days of hospitalization, she was discharged without any significant residual neurologic deficits.

Case 6

A 25-year-old woman with newly diagnosed HIV (CD4⁺ T-cell count of 93 cells/μL), presented to the hospital 3 months postpartum with a 2-month history of stiff neck, confusion, right-sided weakness, fevers, and cough in the setting of recent ART initiation 2 weeks prior. She had severe meningism, a cranial nerve VII palsy, and right-sided hemiparesis with a GCS score of 11/15. An LP revealed an opening pressure of 280 mm H₂O and noninflammatory findings, but positive

CSF Xpert MTB/RIF Ultra and urine FujiLAM (Fujifilm SILVAMP TB-LAM, Fujifilm, Japan). Urine Alere LAM and Xpert MTB/RIF Ultra were negative. A head CT demonstrated multiple infarcts in the left caudate and thalamic area with meningeal enhancement. She was treated for definite TB meningitis and possible postpartum IRIS with standard TB meningitis treatment. Her ART was held during hospitalization. She was discharged without neurologic impairment.

Case 7

A 38-year-old woman with HIV who had been nonadherent to ART for 6 months presented to the hospital 2 months postpartum with 2–3 months of fever, cough, and weight loss. She was found to have lower limb weakness, meningism with a positive Kernig sign, and a GCS score of 13/15. An LP revealed an opening pressure of 70 mm H₂O and demonstrated minimal inflammation with a negative CSF Xpert MTB/RIF Ultra. Urine TB tests were negative. A chest radiograph demonstrated hilar adenopathy with bilateral opacities and tracheal deviation. She was treated for presumptive TB meningitis with standard therapy and discharged without neurologic impairment.

Case 8

A 28-year-old woman with HIV on ART for 4 years presented at 28 weeks of gestation with 2 weeks of headache and photophobia, 1 week of fevers, and 4 days of confusion. She had a positive Kernig sign and a GCS score of 15/15. An LP revealed an opening pressure of 170 mm H₂O in addition to neutrophilic pleocytosis, hypoglycorrhachia, elevated protein, and CSF lactate. CSF cryptococcal antigen, Gram stain, AFB stain, and Xpert MTB/RIF Ultra were negative. A urine Xpert MTB/RIF Ultra was negative; however, urine TB-LAM was positive. The patient was subsequently treated for presumptive TB meningitis and possible bacterial meningitis with standard therapy and was discharged without any neurologic deficits.

Systematic Literature Review

Of 72 titles/abstracts identified, 42 were excluded (18 were unavailable in English, 15 were unrelated to TB meningitis, and 9 were unrelated to pregnancy) (Figure 1). The remaining 30 articles underwent full text review, and their citations revealed an additional 2 articles related to cases of TB meningitis associated with pregnancy. Among these 32 articles, a total of 40 cases of TB meningitis in pregnancy and the postpartum period were identified (Table 1) [28, 33–63].

All Combined Cases

Of all combined cases of TB meningitis associated with pregnancy in this case series and systematic literature review (n = 48), the median age was 27 years (interquartile range [IQR], 23.5–32 years) for those with age provided (39/48). Half of the cases (24/48 [50%]) occurred during pregnancy: 1 in the

first trimester (1–12 weeks), 16 in the second trimester (13–28 weeks), and 3 in the third trimester (29 weeks–delivery), and 4 had undisclosed or indeterminate estimated gestational age. The remainder (24/48 [50%]) occurred either in the postpartum period ($n = 20$) or following a miscarriage or pregnancy termination ($n = 4$) (Supplementary Figure 1). Nine of the 24 cases that first occurred during pregnancy (38%) were reported to have worsening of symptoms or relapse of disease following pregnancy loss or delivery [35, 37, 39, 46, 49, 50, 53, 58, 59], 3 of which were reported as due to medication nonadherence or patient lost to follow-up [46, 58, 59].

Of the previously reported cases, 58% (23/40) did not report HIV status, and 43% (17/40) reported the patient was HIV negative or immunocompetent. The median duration of symptoms was 16 days (IQR, 14–28 days) among those reported (31/48 [65%]). A misdiagnosis or possible delay in diagnosis was reported in 33% of cases (16/48), including 2 herein [33, 38, 39, 41–43, 49, 51, 52, 59, 63]. Maternal mortality was 23% (11/48) and fetal/neonatal mortality was 30% (13/44). Of those women who survived, 30% (11/37) were reported to have residual neurologic deficits. Three of the cases described within (cases 4–6) had recent ART initiation, which may have predisposed them to postpartum ART-related IRIS.

DISCUSSION

Data pertaining to TB meningitis outcomes in pregnancy and peripartum period are sparse despite TB being a leading cause of death among women of reproductive age. This is the first case series and first systematic review of pregnancy-related TB meningitis in women living with HIV/AIDS. Beyond the 8 cases described here, we identified only 40 additional cases of TB meningitis associated with pregnancy, all of which occurred in women living without HIV. TB meningitis presentations were variable in nature and diagnoses were frequently delayed—often not occurring until the postpartum period. This finding, while likely multifactorial in nature, is consistent with prior studies and may highlight the potential role of postpartum immune reconstitution or paradoxical reactions in those living with or without HIV and TB in pregnancy [15, 64].

Pregnant women may be at an increased risk for various infections, including TB, due to the reduction of Th1 immunity and predominance of Th2 immune responses. The reversal of proinflammatory Th1 cytokines postpartum may permit women to mount a stronger immune response to underlying disease or latent infections, which may result in IRIS and underlie the mechanism of postpartum disease flares of some autoimmune conditions (eg, Graves' disease) [64, 65]. In our case series, we described several cases of possible HIV-associated postpartum TB meningitis IRIS and found that numerous published cases also occurred or worsened during the postpartum period in women without HIV. This finding is consistent with reports

of pulmonary TB, where acute symptom worsening has been documented postpartum [15, 64, 66–69]. While this cannot be entirely associated with immune reconstitution alone, a case series of TB in pregnancy found that 76% (22/29) of cases diagnosed postpartum had no symptoms during pregnancy [28]. Furthermore, other studies have found higher rates of TB in pregnant or postpartum women compared to nonpregnant women [15, 16], highlighting the need for additional work in this area.

We found maternal mortality from TB meningitis in this case series and systematic review to be higher than that of HIV-negative nonpregnant persons (23% vs 17%) [70]. While this finding is limited due to presumed publication bias, overall small sample size, and inadequate ability and/or attempts to detect TB meningitis, the information is nonetheless a helpful starting point. We also found that a third of women who survived had some degree of residual neurologic deficits. This finding is similar to the percentage of adults with physical disabilities as a result of TB meningitis (30% vs 32%) [70]; however, these data may not have been systematically captured. Pregnant and postpartum women may be at increased risk for TB meningitis-associated neurological deficits in part due to thromboembolic phenomenon such as arterial stroke or central venous sinus thrombosis with increased coagulability and propensity for clot formation due to pregnancy.

Early diagnosis and treatment of TB meningitis and associated IRIS is paramount in improving outcomes [71]. In this study, we found that over a third of all cases had a delay in diagnosis. Delays in both symptom recognition and diagnostic turnaround time were key barriers. Diagnostic delay may occur as nonspecific symptoms such as fatigue and poor appetite may be attributed to pregnancy itself, or incorrectly attributed to obstetric complications such as postpartum psychosis or puerperal sepsis (as highlighted in our case series). Delays in tuberculous diagnostic test results combined with inadequate test sensitivities further complicated/delayed diagnoses. None of the existing CSF tests for TB meningitis have high enough negative predictive values to rule out disease [72]; thus, providers must rely on multiple test results, maintain a high index of suspicion, and treat if the clinical picture is suggestive regardless of the results (see case 2). Diagnosis of TB meningitis IRIS is also difficult [17]; clinicians must focus on the symptom onset in relation to the immune reconstitution—be this due to ART initiation or cessation of pregnancy.

Importantly, the treatment of choice for pregnant women with TB meningitis does not presently differ from that of nonpregnant people. All patients should receive rifampicin, isoniazid, pyrazinamide, and ethambutol for 2 months followed by rifampicin and isoniazid for 7–10 months. Pyrazinamide in pregnancy is controversial in the United States but is recommended by the World Health Organization for treatment of pregnant persons and is utilized for the first 2 months of

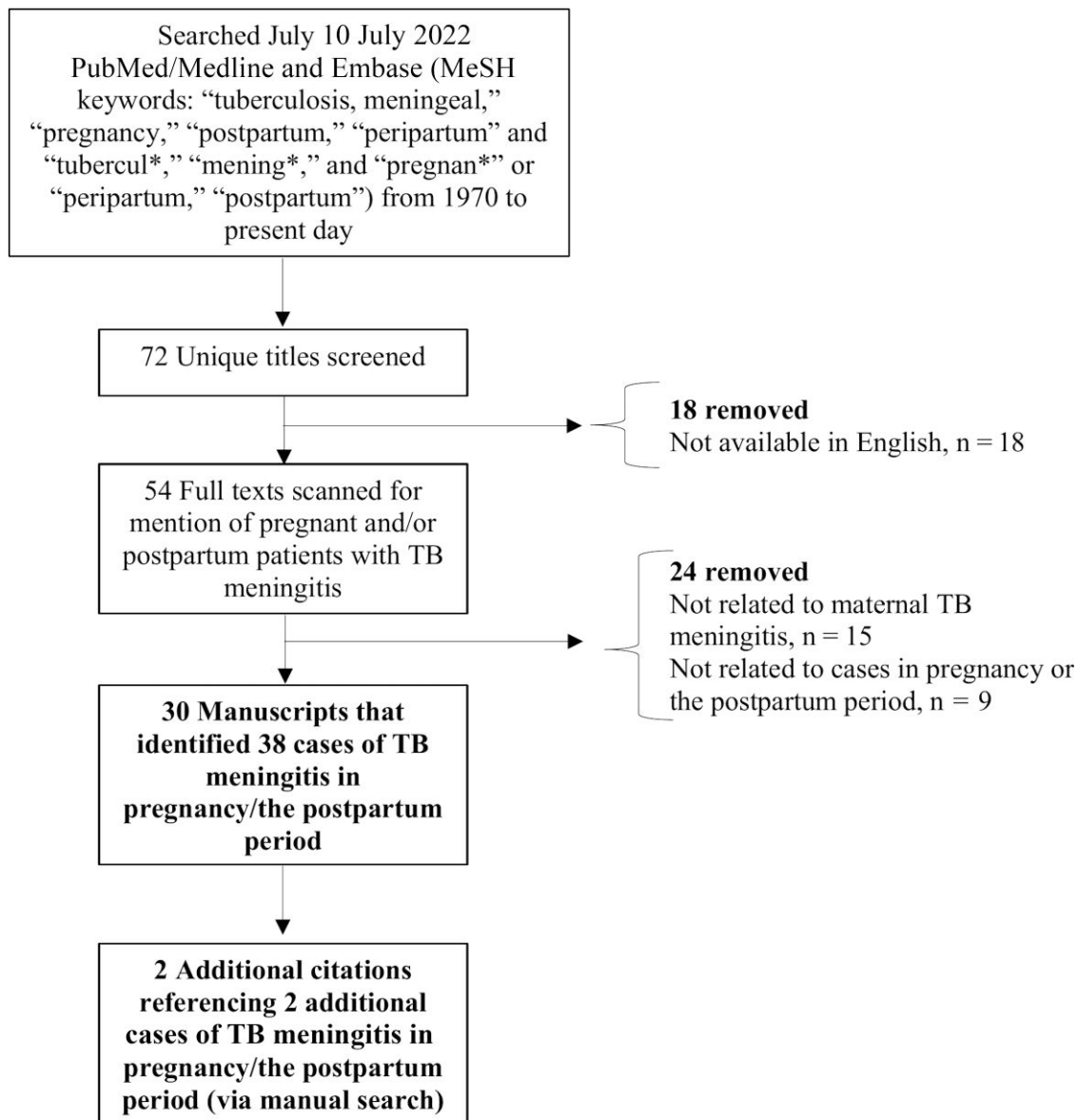


Figure 1. Consolidated Standards of Reporting Trials (CONSORT) flow diagram of literature search. Abbreviations: MeSH, Medical Subject Heading; TB, tuberculous.

treatment in nonpregnant persons with TB meningitis [73]. Overall, standard TB medications are thought to be generally safe in pregnancy [74], but carry an increased risk of hepatitis, peripheral neurotoxicity with isoniazid, and rare reports of congenital abnormalities or hemorrhagic disease with rifampicin. Streptomycin should be avoided due to fetal ototoxicity [65]. Moxifloxacin and other fluoroquinolones are often avoided due to concern for arthropathy in animals; however, there are a few small studies and case reports of fluoroquinolones being safely used in pregnancy [75–77]. For women living with HIV diagnosed with TB meningitis, providers must carefully consider when to initiate ART. In nonpregnant persons, ART is usually delayed until after 4–8 weeks of TB treatment initiation given the increased risk of adverse events in patients who

have shorter duration of time between TB therapy and ART [78, 79]. In pregnant women, providers must assess the risk of possible ART-associated IRIS and the risk of mother-to-child HIV transmission, where there is a clear imperative to start ART immediately.

In people with TB meningitis-associated IRIS, higher-dose corticosteroids are recommended in addition to antimycobacterial therapy. Short courses of antenatal corticosteroids (ie, ≤ 10 days) are frequently utilized to promote fetal lung maturity in women at high risk for preterm delivery and in treatment of coronavirus disease 2019. However, prolonged use has been associated with negative fetal/neonatal outcomes [80]. Providers therefore should weigh the risks and benefits of the utilization of fluorinated steroids (eg, dexamethasone), which have higher

rates of placental transfer, as opposed to nonfluorinated steroids (eg, prednisolone) in pregnant patients with TB meningitis who may require prolonged steroid courses [81, 82]. Other immunosuppressive agents can be considered in select cases, but safety in pregnancy must be considered as, for instance, thalidomide (used selectively in pediatric TB meningitis) would not be an option due to teratogenicity [17, 83]. It is vital to note that there are no research studies on which to base TB meningitis treatment recommendations in pregnancy, as this population has been systematically excluded from clinical research on the topic, including within our own trials described above. Many questions remain regarding whether pregnant patients should be managed in the same way as nonpregnant adults given the multiple pregnancy-related physiological changes.

Our case series and systematic review has several limitations. First, we did not assess publications related to general TB in pregnancy, which may have contained additional cases of meningitis. Second, our report cannot establish the true incidence of TB meningitis in pregnancy or the postpartum period. Third, while we noted a high proportion of cases presenting postpartum, this may be due to a multitude of factors such as the patient being present in postpartum care, potentially without engagement in care prior to birth, as opposed to theorized immune reconstitution alone. Additional considerations should be made for screening for latent TB infection in pregnancy particularly for those living with HIV and in endemic areas as is encouraged by the World Health Organization [74]. Potential benefits from screening and TB preventive treatment in pregnancy have been described [84, 85] and trials evaluating this in pregnancy have been completed [86–88], including a safety pharmacokinetic study of a 3-month regimen of isoniazid and rifampin [89].

CONCLUSIONS

Pregnant women may be at increased risk for TB and TB meningitis due to various immunologic changes and immune reconstitution postpartum. We found limited literature on TB meningitis associated with pregnancy despite TB being a leading cause of death in women of reproductive age. With unacceptably high rates of mortality and neurologic morbidity among pregnant or recently pregnant women as described in this study, providers should maintain a high index of suspicion and consider screening for TB during pregnancy, particularly in endemic areas. Additional descriptive epidemiological work examining both disease burden and clinical outcomes of TB and other advanced opportunistic infections associated with pregnancy are needed.

Supplementary Data

Supplementary materials are available at *Open Forum Infectious Diseases* online. Consisting of data provided by the authors to benefit the reader, the posted materials are not copyedited and are the sole responsibility of the

authors, so questions or comments should be addressed to the corresponding author.

Notes

Financial Support. This research is supported by the National Institute of Neurological Disorders and Stroke (award number K23NS110470 to N. C. B.); the Fogarty International Center (grant number R01NS086312); and the National Institute of Allergy and Infectious Diseases (grant number R01AI162786 to D. R. B.). F. V. C. is supported by a UK National Institute for Health and Care Research Academic Clinical Lectureship (award number CL-2020-27-001).

Potential conflicts of interest. The authors: No reported conflicts.

All authors have submitted the ICMJE Form for Disclosure of Potential Conflicts of Interest. Conflicts that the editors consider relevant to the content of the manuscript have been disclosed.

References

- Sugarman J, Colvin C, Moran AC, Oxlade O. Tuberculosis in pregnancy: an estimate of the global burden of disease. *Lancet Glob Health* 2014; 2:e710–6.
- Dodd PJ, Osman M, Cresswell FV, et al. The global burden of tuberculous meningitis in adults: a modelling study. *PLoS Global Public Health* 2021; 1:e0000069.
- Heemskerck AD, Bang ND, Mai NT, et al. Intensified antituberculous therapy in adults with tuberculous meningitis. *N Engl J Med* 2016; 374:124–34.
- Thwaites GE, Nguyen DB, Nguyen HD, et al. Dexamethasone for the treatment of tuberculous meningitis in adolescents and adults. *N Engl J Med* 2004; 351:1741–51.
- Torok ME, Yen NT, Chau TT, et al. Timing of initiation of antiretroviral therapy in human immunodeficiency virus (HIV)–associated tuberculous meningitis. *Clin Infect Dis* 2011; 52:1374–83.
- Cresswell FV, Bangdiwala AS, Bahr NC, et al. Can improved diagnostics reduce mortality from tuberculous meningitis? Findings from a 6.5-year cohort in Uganda. *Wellcome Open Res* 2018; 3:64.
- Misra UK, Kalita J, Nair PP. Role of aspirin in tuberculous meningitis: a randomized open label placebo controlled trial. *J Neurol Sci* 2010; 293:12–7.
- Poole JA, Claman HN. Immunology of pregnancy. Implications for the mother. *Clin Rev Allergy Immunol* 2004; 26:161–70.
- Wilczyński JR. Th1/Th2 cytokines balance—yin and yang of reproductive immunology. *Eur J Obstet Gynecol Reprod Biol* 2005; 122:136–43.
- Clark DA, Croitoru K. TH1/TH2,3 Imbalance due to cytokine-producing NK, gammadelta T and NK-gammadelta T cells in murine pregnancy decidua in success or failure of pregnancy. *Am J Reprod Immunol* 2001; 45:257–65.
- Elenkov IJ, Wilder RL, Bakalov VK, et al. IL-12, TNF-alpha, and hormonal changes during late pregnancy and early postpartum: implications for autoimmune disease activity during these times. *J Clin Endocrinol Metab* 2001; 86:4933–8.
- Rook GA. Th2 cytokines in susceptibility to tuberculosis. *Curr Mol Med* 2007; 7:327–37.
- Ashenafi S, Aderaye G, Bekele A, et al. Progression of clinical tuberculosis is associated with a Th2 immune response signature in combination with elevated levels of SOCS3. *Clin Immunol* 2014; 151:84–99.
- Bothamley GH, Ehlers C, Salonga I, et al. Pregnancy in patients with tuberculosis: a TBNET cross-sectional survey. *BMC Pregnancy Childbirth* 2016; 16:304.
- Zenner D, Kruijshaar ME, Andrews N, Abubakar I. Risk of tuberculosis in pregnancy: a national, primary care-based cohort and self-controlled case series study. *Am J Respir Crit Care Med* 2012; 185:779–84.
- Jonsson J, Kühlmann-Berenzon S, Berggren I, Bruchfeld J. Increased risk of active tuberculosis during pregnancy and postpartum: a register-based cohort study in Sweden. *Eur Respir J* 2020; 55:1901886.
- Bahr N, Boulware DR, Marais S, Scriven J, Wilkinson RJ, Meintjes G. Central nervous system immune reconstitution inflammatory syndrome. *Curr Infect Dis Rep* 2013; 15:583–93.
- Cheng VC, Ho PL, Lee RA, et al. Clinical spectrum of paradoxical deterioration during antituberculous therapy in non-HIV-infected patients. *Eur J Clin Microbiol Infect Dis* 2002; 21:803–9.
- Bacha JM, El-Mallawany NK, Slone JS, Wilkinson JP, Mehta PS, Campbell LR. Recommendations for treating life-threatening Kaposi sarcoma during pregnancy in HIV-positive women in low income countries. *Int J STD AIDS* 2020; 31:724–34.
- Adeyemo A, Wood C, Govind A. Kaposi's sarcoma in pregnancy after initiation of highly active antiretroviral therapy: a manifestation of immune reconstitution syndrome. *Int J STD AIDS* 2012; 23:905–6.
- Caby F, Lemerrier D, Coulomb A, et al. Fetal death as a result of placental immune reconstitution inflammatory syndrome. *J Infect* 2010; 61:185–8.

22. Miyoshi S, Oda N, Gion Y, et al. Exacerbation of pulmonary cryptococcosis associated with enhancement of Th2 response in the postpartum period. *J Infect Chemother* **2021**; 27:1248–50.
23. Mittal N, Vatsa S, Minz A. Fatal meningitis by *Cryptococcus laurentii* in a postpartum woman: a manifestation of immune reconstitution inflammatory syndrome. *Indian J Med Microbiol* **2015**; 33:590–3.
24. Yokoyama T, Kadowaki M, Yoshida M, Suzuki K, Komori M, Iwanaga T. Disseminated cryptococcosis with marked eosinophilia in a postpartum woman. *Intern Med* **2018**; 57:135–9.
25. Ishikawa D, Maruyama T, Nakamura T, et al. Postpartum paradoxical expansion of cerebrotubercular lesions associated with *Cryptococcus gattii* meningoencephalitis. *Clin Neurol Neurosurg* **2020**; 196:105955.
26. Kiggundu R, Rhein J, Meya DB, Boulware DR, Bahr NC. Unmasking cryptococcal meningitis immune reconstitution inflammatory syndrome in pregnancy induced by HIV antiretroviral therapy with postpartum paradoxical exacerbation. *Med Mycol Case Rep* **2014**; 5:16–9.
27. Pastick KA, Nalintya E, Tugume L, et al. Cryptococcosis in pregnancy and the postpartum period: case series and systematic review with recommendations for management. *Med Mycol* **2020**; 58:282–92.
28. Cheng VC, Woo PC, Lau SK, et al. Peripartum tuberculosis as a form of immunorestitution disease. *Eur J Clin Microbiol Infect Dis* **2003**; 22:313–7.
29. Ellis J, Bangdiwala AS, Cresswell FV, et al. The changing epidemiology of HIV-associated adult meningitis, Uganda 2015–2017. *Open Forum Infect Dis* **2019**; 6:ofz419.
30. Rajasingham R, Rhein J, Klammer K, et al. Epidemiology of meningitis in an HIV-infected Ugandan cohort. *Am J Trop Med Hyg* **2015**; 92:274–9.
31. Cresswell FV, Ssebambulidde K, Grint D, et al. High dose oral and intravenous rifampicin for improved survival from adult tuberculous meningitis: a phase II open-label randomised controlled trial (the RiT study). *Wellcome Open Res* **2018**; 3:83.
32. Cresswell FV, Meya DB, Kagimu E, et al. High-dose oral and intravenous rifampicin for the treatment of tuberculous meningitis in predominantly human immunodeficiency virus (HIV)-positive Ugandan adults: a phase II open-label randomized controlled trial. *Clin Infect Dis* **2021**; 73:876–84.
33. Ye R, Wang C, Zhao L, Wu X, Gao Y, Liu H. Characteristics of miliary tuberculosis in pregnant women after in vitro fertilisation and embryo transfer. *Int J Tuberc Lung Dis* **2019**; 23:136–9.
34. Namani S, Dreshaj S, Berisha AZ. Tuberculous meningoencephalitis associated with brain tuberculomas during pregnancy: a case report. *J Med Case Rep* **2017**; 11:175.
35. Nakatani Y, Suto Y, Fukuma K, et al. Intrathecal isoniazid for refractory tuberculous meningitis with cerebral infarction. *Intern Med* **2017**; 56:953–7.
36. Baidya DK, Tripathi A, Menon S, Garg R. Anaesthetic management of emergency caesarean section in a patient with seizures and likely raised intracranial pressure due to tuberculous meningitis. *Anaesth Intensive Care* **2011**; 39:951–3.
37. Yeh S, Cunningham MA, Patronas N, Forozaan R. Optic neuropathy and perichiasmal tuberculomas associated with *Mycobacterium tuberculosis* meningitis in pregnancy. *Can J Ophthalmol* **2009**; 44:713–5.
38. Jana N, Rakshit BM, Trivedi G. Tuberculous meningitis in early pregnancy mimicking hyperemesis gravidarum: a diagnostic challenge. *J Obstet Gynaecol* **2008**; 28:530–1.
39. Prevost MR, Fung Kee Fung KM. Tuberculous meningitis in pregnancy—implications for mother and fetus: case report and literature review. *J Matern Fetal Med* **1999**; 8:289–94.
40. Clark WC, Metcalf JC, Jr., Muhlbauer MS, Dohan FC Jr, Robertson JH. *Mycobacterium tuberculosis* meningitis: a report of twelve cases and a literature review. *Neurosurgery* **1986**; 18:604–10.
41. Kingdom JC, Kennedy DH. Tuberculous meningitis in pregnancy. *Br J Obstet Gynaecol* **1989**; 96:233–5.
42. Ray J, Landis S, Oczkowski W, King D. A woman with tuberculous meningitis peripartum. *J SOG* **1997**; 19:186–8.
43. Liu C, Christie LJ, Neely J, et al. Tuberculous meningoencephalitis in a pregnant woman presenting 7 years after removal of a cerebral granuloma. *Eur J Clin Microbiol Infect Dis* **2008**; 27:233–6.
44. Kutlu T, Tugrul S, Aydin A, Oral O. Tuberculous meningitis in pregnancy presenting as hyperemesis gravidarum. *J Matern Fetal Neonatal Med* **2007**; 20:357–9.
45. Chan KH, Ho PL, Cheung RT, et al. Tuberculous meningitis with tuberculomata presenting as postpartum pyrexia of unknown origin. *Hosp Med* **2003**; 64:306–7.
46. Heywood S, Amoa AB, Mola GL, Klufio CA. A survey of pregnant women with tuberculosis at the Port Moresby General Hospital. *P N G Med J* **1999**; 42:63–70.
47. Jana N, Vasishta K, Saha SC, Ghosh K. Obstetrical outcomes among women with extrapulmonary tuberculosis. *N Engl J Med* **1999**; 341:645–9.
48. Ogawa SK, Smith MA, Brennessel DJ, Lowy FD. Tuberculous meningitis in an urban medical center. *Medicine (Baltimore)* **1987**; 66:317–26.
49. McIntyre PB, McCormack JG, Vacca A. Tuberculosis in pregnancy—implications for antenatal screening in Australia. *Med J Aust* **1987**; 146:42–4.
50. Stands JW, Jowers RG, Bryan CS. Miliary-meningeal tuberculosis during pregnancy: case report, and brief survey of the problem of extra-pulmonary tuberculosis. *J S C Med Assoc* **1977**; 73:282–5.
51. Petrini B, Gentz J, Winbladh B, Skoldenberg B, Westin B. Perinatal transmission of tuberculosis: meningitis in mother, disseminated disease in child. *Scand J Infect Dis* **1983**; 15:403–5.
52. Brandstetter RD, Murray HW, Mellow E. Tuberculous meningitis in a puerperal woman. *JAMA* **1980**; 244:2440.
53. Chambers CH, Komorowski R. Fulminant tuberculous meningitis in a gravid female. *Wis Med J* **1975**; 74:121–3.
54. Gordon-Nesbitt DC, Rajan G. Congenital tuberculosis successfully treated. *Br Med J* **1973**; 1:233–4.
55. Golditch IM. Tuberculous meningitis and pregnancy. *Am J Obstet Gynecol* **1971**; 110:1144–6.
56. Romero-Imbroda J, Sagrario-Fustero T, Del Canto-Pérez C, Requena-Pou M. Postpartum meningoencephalitis and spinal tuberculosis. *Neurologia (Engl Ed)* **2020**; 35:349–50.
57. Saleh A, Mohammed AA, Raines P. An unexpected cause of right heart strain. *BMJ Case Rep* **2013**; 2013:bcr2013200216.
58. Shibolet S, Dan M, Jedwab M, Goldhammer Y, Baum GL. Recurrent miliary tuberculosis secondary to infected ventriculoatrial shunt. *Chest* **1979**; 76:328–30.
59. Meyers BR, Hirschman SZ. Unusual presentations of tuberculous meningitis. *Mt Sinai J Med* **1974**; 41:407–11.
60. Wilson EA, Thelin TJ, Dilts PV Jr. Tuberculosis complicated by pregnancy. *Am J Obstet Gynecol* **1973**; 115: 526–9.
61. Meregildo-Rodríguez ED, Chiroque MV, Rodríguez Llanos JR, Sánchez Carrillo HC, Vilchez Rivera S, Delgado Sánchez MC. First case report of tuberculous meningitis secondary to endometrial tuberculosis following a clandestine abortion. *Infez Med* **2020**; 28:82–6.
62. Smitha M, Saraswathi K. Tuberculous meningitis in pregnancy—a rare case report. *Int J Pharma Bio Sci* **2013**; 5:B1164–7.
63. Samson Ejiji I, Gomerep S, Johnson M, Basil Bemgba A. Delayed diagnosis of tuberculous meningitis in a pregnant Nigerian: a case report. *Int J Mycobacteriol* **2013**; 2:54–7.
64. Singh N, Perfect JR. Immune reconstitution syndrome and exacerbation of infections after pregnancy. *Clin Infect Dis* **2007**; 45:1192–9.
65. Mathad JS, Gupta A. Tuberculosis in pregnant and postpartum women: epidemiology, management, and research gaps. *Clin Infect Dis* **2012**; 55:1532–49.
66. Myers JP, Perlstein PH, Light IJ, Towbin RB, Dincsoy HP, Dincsoy MY. Tuberculosis in pregnancy with fatal congenital infection. *Pediatrics* **1981**; 67: 89–94.
67. Maheswaran C, Neuwirth RS. An unusual case of postpartum fever. *Acute hematogenous tuberculosis. Obstet Gynecol* **1973**; 41:765–9.
68. D'Cruz IA, Dandekar AC. Tuberculous meningitis in pregnant and puerperal women. *Obstet Gynecol* **1968**; 31:775–8.
69. Brar HS, Golde SH, Egan JE. Tuberculosis presenting as puerperal fever. *Obstet Gynecol* **1987**; 70:488–90.
70. Stadelman AM, Ellis J, Samuels THA, et al. Treatment outcomes in adult tuberculous meningitis: a systematic review and meta-analysis. *Open Forum Infect Dis* **2020**; 7:ofaa257.
71. Bahr NC, Meintjes G, Boulware DR. Inadequate diagnostics: the case to move beyond the bacilli for detection of meningitis due to *Mycobacterium tuberculosis*. *J Med Microbiol* **2019**; 68:755–60.
72. Bahr NC, Marais S, Caws M, et al. Genexpert MTB/RIF to diagnose tuberculous meningitis: perhaps the first test but not the last. *Clin Infect Dis* **2016**; 62:1133–5.
73. World Health Organization. Guidelines for treatment of tuberculosis, 4th ed. http://apps.who.int/iris/bitstream/handle/10665/44165/9789241547833_eng.pdf?sequence=1. Accessed 12 February 2022.
74. World Health Organization. WHO consolidated guidelines on tuberculosis. <https://apps.who.int/iris/bitstream/handle/10665/331170/9789240001503-eng.pdf>. Accessed 12 February 2022.
75. Loveday M, Hughes J, Sunkari B, et al. Maternal and infant outcomes among pregnant women treated for multidrug/rifampicin-resistant tuberculosis in South Africa. *Clin Infect Dis* **2021**; 72:1158–68.
76. Alene KA, Murray MB, van de Water BJ, et al. Treatment outcomes among pregnant patients with multidrug-resistant tuberculosis: a systematic review and meta-analysis. *JAMA Netw Open* **2022**; 5:e2216527.
77. Van Kampenhout E, Bolhuis MS, Alffenaar JC, et al. Pharmacokinetics of moxifloxacin and linezolid during and after pregnancy in a patient with multidrug-resistant tuberculosis. *Eur Respir J* **2017**; 49:1601724.
78. Blanc FX, Sok T, Laureillard D, et al. Earlier versus later start of antiretroviral therapy in HIV-infected adults with tuberculosis. *N Engl J Med* **2011**; 365:1471–81.

79. Karim SS A, Naidoo K, Grobler A, et al. Integration of antiretroviral therapy with tuberculosis treatment. *N Engl J Med* **2011**; 365:1492–501.
80. Saad AF, Chappell L, Saade GR, Pacheco LD. Corticosteroids in the management of pregnant patients with coronavirus disease (COVID-19). *Obstet Gynecol* **2020**; 136:823–6.
81. Whitelaw A, Thoresen M. Antenatal steroids and the developing brain. *Arch Dis Child Fetal Neonatal Ed* **2000**; 83:F154–7.
82. Murphy VE, Fittock RJ, Zarzycki PK, Delahunty MM, Smith R, Clifton VL. Metabolism of synthetic steroids by the human placenta. *Placenta* **2007**; 28:39–46.
83. van Toorn R, Zaharie SD, Seddon JA, et al. The use of thalidomide to treat children with tuberculosis meningitis: a review. *Tuberculosis (Edinb)* **2021**; 130: 102125.
84. Gupta A, Nayak U, Ram M, et al. Postpartum tuberculosis incidence and mortality among HIV-infected women and their infants in Pune, India, 2002–2005. *Clin Infect Dis* **2007**; 45:241–9.
85. Malhamé I, Cormier M, Sugarman J, Schwartzman K. Latent tuberculosis in pregnancy: a systematic review. *PLoS One* **2016**; 11:e0154825.
86. Gupta A, Montepiedra G, Aaron L, et al. Isoniazid preventive therapy in HIV-infected pregnant and postpartum women. *N Engl J Med* **2019**; 381:1333–46.
87. Theron G, Montepiedra G, Aaron L, et al. Individual and composite adverse pregnancy outcomes in a randomized trial on isoniazid preventative therapy among women living with human immunodeficiency virus. *Clin Infect Dis* **2021**; 72: e784–90.
88. Salazar-Austin N, Cohn S, Lala S, et al. Isoniazid preventive therapy and pregnancy outcomes in women living with human immunodeficiency virus in the Tshepiso cohort. *Clin Infect Dis* **2020**; 71:1419–26.
89. Mathad JS, Savic R, Britto P, et al. Pharmacokinetics and safety of 3 months of weekly rifampentine and isoniazid for tuberculosis prevention in pregnant women. *Clin Infect Dis* **2022**; 74:1604–13.