

LONDON  
SCHOOL of  
HYGIENE  
& TROPICAL  
MEDICINE



LSHTM Research Online

Wootton, CI; Elliott, IAM; Sengdetkha, D; Vongsouvath, M; Phongmany, S; Dance, DAB; (2013) Melioidosis: an unusual cause of recurrent buttock abscesses. *CLINICAL AND EXPERIMENTAL DERMATOLOGY*, 38 (4). pp. 427-428. ISSN 0307-6938 DOI: <https://doi.org/10.1111/j.1365-2230.2012.04469.x>

Downloaded from: <http://researchonline.lshtm.ac.uk/4652781/>

DOI: <https://doi.org/10.1111/j.1365-2230.2012.04469.x>

**Usage Guidelines:**

Please refer to usage guidelines at <https://researchonline.lshtm.ac.uk/policies.html> or alternatively contact [researchonline@lshtm.ac.uk](mailto:researchonline@lshtm.ac.uk).

Available under license: Creative Commons Attribution Non-commercial  
<http://creativecommons.org/licenses/by-nc/3.0/>

<https://researchonline.lshtm.ac.uk>

Dermatology, Hospital de Sant Pau i Santa Tecla, Tarragona, Spain;

<sup>3</sup>Department of Dermatology, Medical University of Graz, Graz,

Austria; <sup>4</sup>State Clinic of Dermatology, Hospital of Skin and Venereal

Diseases, Thessaloniki, Greece; <sup>5</sup>Dermatology Center, Nemours,

France; and <sup>6</sup>Clinic of Dermatovenereology, Clinical Center of Nis,

Medical Faculty, University of Nis, Nis, Serbia

E-mail: emlallas@gmail.com

Conflict of interest: none declared.

Accepted for publication 27 December 2012

## References

- 1 James W, Berger T, Elston D. Errors in metabolism: necrobiosis lipidica. In: *Andrews' Diseases of the Skin. Clinical Dermatology*, 10th edn (James W, Berger T, Elston D, eds). London: Elsevier Co, 2006; 539–40.
- 2 Li A, Hogan DJ, Sanusi ID, Smoller BR. Granuloma annulare and malignant neoplasms. *Am J Dermatopathol* 2003; **25**: 113–16.
- 3 Lallas A, Kyrgidis A, Tzellos T *et al*. Accuracy of dermoscopic criteria for the diagnosis of psoriasis, dermatitis, lichen planus and pityriasis rosea. *Br J Dermatol* 2012; **166**: 1198–205.
- 4 Bakos RM, Cartell A, Bakos L. Dermatoscopy of early-onset necrobiosis lipidica. *J Am Acad Dermatol* 2012; **66**: e143–4.
- 5 Pellicano R, Todorovic-Zivkovic D, Gourhant JY *et al*. Dermoscopy of cutaneous sarcoidosis. *Dermatology* 2010; **221**: 51–4.

## Melioidosis: an unusual cause of recurrent buttock abscesses

doi: 10.1111/j.1365-2230.2012.04469.x

An 18-year-old woman presented to Mahosot Hospital, Vientiane with a 3-year history of widespread abscess formation and significant scarring of her left buttock. The patient was a rice farmer from Saravan Province. The lesion had initially started as a small painless pustule, without preceding trauma or injection. It had grown in size, and had been treated with incision and drainage and a week's course of ampicillin. However, the lesion persisted, and further abscesses developed despite subsequent (self-initiated) ampicillin therapy and treatment from a traditional Lao healer. The patient remained systemically well throughout with no fever or other symptoms.

On physical examination, areas of atrophic scarring, induration, and discharging sinuses were seen on the patient's left buttock (Fig. 1). The remainder of the buttock area was clear, and the rest of the clinical examination was unremarkable.

Blood tests revealed that the patient had microcytic anaemia, with haemoglobin 8.2 g/L (normal range 11.5–16.5 g/L) and mean corpuscular volume 50 fL (80–96 fL). Glucose and creatinine were within normal ranges, and screening for thalassaemia gave negative results.

There was no growth from two sets of blood cultures. A pus culture yielded a pure growth of an oxidase-positive Gram-negative rod with a metallic sheen on blood agar, which was confirmed as *Burkholderia pseudomallei* by a biochemical test kit (API20NE; bio-Merieux, Marcy L'Etoile, France).

A chest radiograph was normal, but abdominal ultrasonography identified splenic microabscesses (Fig. 2). A fistulogram of the left buttock demonstrated no connection with underlying deep structures (Fig. 3). Ultrasonography of the buttock revealed a collection of pus within the soft tissue, 80 × 10 mm in size, which was drained percutaneously.

A diagnosis of melioidosis was made, and the patient was treated with intravenous ceftazidime (2 g

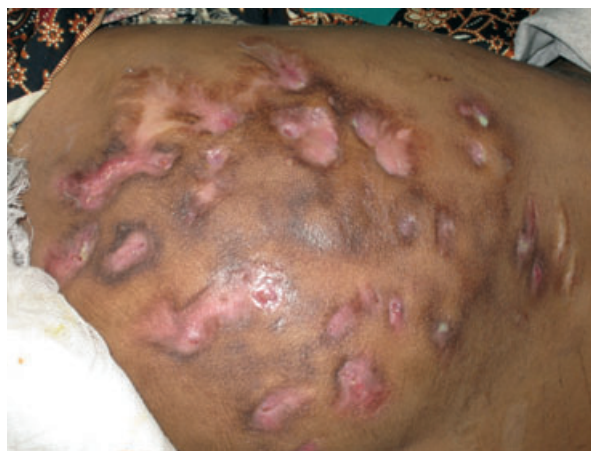

Figure 1 Cutaneous melioid affecting the buttock.

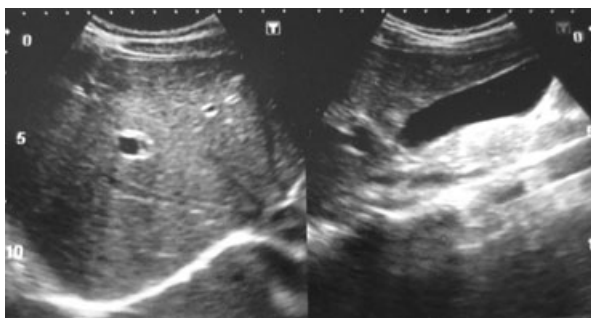
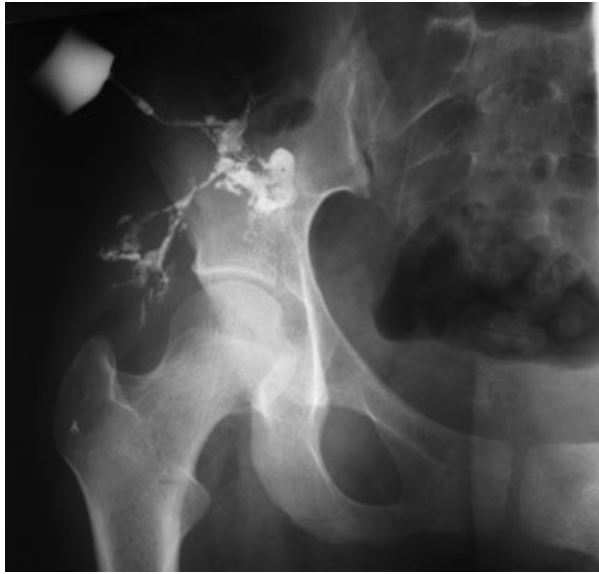


Figure 2 Ultrasound scan of splenic microabscesses.



**Figure 3** Fistulogram of buttock lesion.

three times daily) for 3 weeks because of the delay in abscess drainage, evidence of splenic involvement and persistently culture-positive pus samples. The patient was discharged on a combination of oral cotrimoxazole (240/1200 mg twice daily) and doxycycline (200 mg once daily) for a further 16 weeks. At 3 months, there was marked improvement, with only one small sinus present without significant pus discharge. A swab of the site was culture-negative.

Melioidosis is the clinical manifestation of infection with *B. pseudomallei*, a ubiquitous saprophytic environmental bacterium that resides in the water and soil of predominantly tropical climates, most notably south-east Asia and northern Australia.<sup>1</sup> The area from where the patient originated, Saravan Province, is known to have a high prevalence of *B. pseudomallei* in the soil. Typically, infection occurs when working closely with soil, such as in paddy fields. Direct inoculation through breaks in the skin barrier and inhalation are recognized modes of transmission. Systemic disease, with or without dissemination, is typical, but localized cutaneous and soft-tissue disease is well described, and accounts for around 12–24% of clinical presentations of melioidosis.<sup>2</sup> Skin presentations include subcutaneous abscesses, pustules, wound infections, cellulitis, and granulomatous lesions. Mortality ranges from 20% to 50% in Australia and Thailand, respectively.<sup>3</sup> Although melioidosis is almost exclusively a disease of tropical climates, sporadic imported cases do occur among both immigrants and adventure tourists.<sup>4</sup>

This case was particularly interesting because of the extensive nature of the disease and long history, resulting in significant scarring that is unlikely to improve with treatment.

**C. I. Wootton,\*† I. A. M. Elliott,†‡ D. Sengdetkha,† M. Vongsouvat,† S. Phongmany,§ and D. A. B. Dance†‡**

\*Department of Dermatology, Queen's Medical Centre, Nottingham, UK;

†Microbiology Laboratory, Lao-Oxford-Mahosot Hospital

Wellcome-Trust Research Unit, Mahosot Hospital, Vientiane, Lao

People's Democratic Republic; ‡ Centre for Clinical Vaccinology and

Tropical Medicine, Churchill Hospital, University of Oxford, UK; and

§Adult Infectious Diseases ward, Mahosot Hospital, Vientiane, Lao

People's Democratic Republic

E-mail: ciwootton@aol.com

Conflict of interest: none declared.

Accepted for publication 27 December 2012

Re-use of this article is permitted in accordance with the Terms and Conditions set out at [http://wileyonlinelibrary.com/onlineopen#OnlineOpen\\_Terms](http://wileyonlinelibrary.com/onlineopen#OnlineOpen_Terms).

## References

- 1 Phetsouvanh R, Phongmany S, Newton PN *et al*. Melioidosis and Pandora's box in Lao PDR. *Clin Infect Dis* 2001; **32**: 653–4.
- 2 Gibney KB, Cheng AC, Currie BJ. Cutaneous melioidosis in the tropical top end of Australia: a prospective study and review of the literature. *Clin Infect Dis* 2008; **47**: 603–9.
- 3 Cheng AC, Currie BJ. Melioidosis: epidemiology, pathophysiology and management. *Clin Microbiol Rev* 2005; **18**: 383–416.
- 4 Meckenstock R, Therby A, Marque-Juillet S *et al*. Cutaneous melioidosis in adolescent returning from Guadeloupe. *Emerg Infect Dis* 2012; **18**: 359–60.

## Skin surveillance and reduction of immunosuppression after failure of renal transplant

doi: 10.1111/j.1365-2230.2012.04474.x

Organ-transplant recipients who receive immunosuppressive agents are known to be at higher risk than the general population of developing skin malignancies, especially squamous cell carcinoma.<sup>1,2</sup> As patients are receiving transplants at older ages and patients with transplants are surviving longer, the number of at-risk patients will continue to increase.

In our unit, every patient with a functioning renal transplant is reviewed annually in a specialist transplant clinic. The patient's skin is examined, and they are given advice about sun-protection measures. Similar models are used by other UK centres. When trans-