

Toluidine Blue 0.05% Vital Staining for Diagnosis of Ocular Surface Squamous Neoplasia in Kenya

Authors:

Stephen Gichuhi, M.Med^{1,2}, Ephantus Macharia, HND³, Joy Kabiru, M.Med³, Alain M'bongo Zindamoyen, M.Med³, Hilary Rono, M.Med⁴, Ernest Ollando, M.Med⁵, Leonard Wanyonyi, HND⁵, Joseph Wachira, M.Med⁶, Rhoda Munene, M.Med⁶, Timothy Onyuma, M.Med⁷, Walter G. Jaoko, PhD⁸, Mandeep S. Sagoo, FRCOphth^{9,10,11}, Helen A. Weiss, PhD¹ and Matthew J. Burton, PhD^{1,10}

Email contacts

Stephen Gichuhi, stephen.gichuhi@lshtm.ac.uk
Ephantus Macharia, machariaew@yahoo.co.uk
Joy Kabiru, joykabiru@yahoo.com
Alain M'bongo Zindamoyen, zindamoyen@yahoo.com
Hilary Rono, hkrono@yahoo.com
Ernest Ollando, eollando@yahoo.com
Leonard Wanyonyi, leosab09@yahoo.com
Joseph Wachira, drjwachira@gmail.com
Rhoda Munene, drmmunene@gmail.com
Timothy Onyuma, tonyuma@mpshahhosp.org
Walter G. Jaoko, wjaoko@kaviuon.org
Mandeep S. Sagoo, mandeep.sagoo@moorfields.nhs.uk
Helen A. Weiss, helen.weiss@lshtm.ac.uk
Matthew J. Burton, matthew.burton@lshtm.ac.uk

Affiliations:

¹London School of Hygiene and Tropical Medicine, Keppel Street, London, WC1E 7HT, UK
²Department of Ophthalmology, University of Nairobi, P.O Box 19676-00202, Nairobi, Kenya
³PCEA Kikuyu Eye Unit, PO Box 45, Kikuyu, Kenya
⁴Kitale District Hospital, PO Box 98-30200, Kitale, Kenya
⁵Sabatia Eye Hospital, PO Box 214-50311, Wodanga, Kenya
⁶Kenyatta National Hospital, PO Box 20723-00202, Nairobi, Kenya
⁷MP Shah Hospital, Department of Pathology, PO Box 14497-00800, Nairobi, Kenya
⁸KAVI Institute of Clinical Research, University of Nairobi, P.O Box 19676-00202, Nairobi, Kenya
⁹UCL Institute of Ophthalmology, 11-43 Bath Street, London EC1V 9EL, UK
¹⁰Moorfields Eye Hospital, 162 City Road, London, EC1V 2PD, UK
¹¹St. Bartholomew's Hospital, W Smithfield, London EC1A 7BE, London, UK

Corresponding Author:

Stephen Gichuhi
International Center for Eye Health
London School of Hygiene & Tropical Medicine
Keppel Street, London WC1E 7HT
United Kingdom
Tel. +44 (20) 7636 8636 ext. 8257
stephen.gichuhi@lshtm.ac.uk

Word count: Abstract 349;Text 2998

52 **Abstract**

53 IMPORTANCE

54 Clinical features are unreliable for distinguishing Ocular Surface Squamous Neoplasia
55 (OSSN) from benign conjunctival lesions.

56

57 OBJECTIVE

58 To evaluate the adverse effects, accuracy and inter-observer variation of Toluidine Blue
59 0.05% vital staining in distinguishing OSSN, confirmed by histopathology, from other
60 conjunctival lesions.

61

62 DESIGN, SETTING AND PARTICIPANTS

63 Cross-sectional study in Kenya from July 2012 through July 2014 of 418 adults with
64 suspicious conjunctival lesions. Pregnant and breastfeeding women were excluded.

65

66 EXPOSURES

67 Comprehensive ophthalmic slit-lamp examination was conducted. Vital staining with
68 Toluidine Blue 0.05% aqueous solution was performed before surgery. Initial safety testing
69 was conducted on large tumours scheduled for exenteration looking for corneal toxicity on
70 histology before testing smaller tumours. We asked about pain or discomfort after staining
71 and evaluated the cornea at the slit lamp for epithelial defects. Lesions were photographed
72 before and after staining. Diagnosis was confirmed by histopathology. Six examiners
73 assessed photographs from a sub-set of 100 consecutive participants for staining and made
74 a diagnosis of OSSN vs Non-OSSN.

75

76 MAIN OUTCOMES AND MEASURES

77 Staining was compared with histopathology to estimate sensitivity, specificity and predictive
78 values. Adverse effects were enumerated. Inter-observer agreement was estimated using
79 the kappa statistic (k).

80

81 RESULTS

82 143/419 (34%) participants had OSSN by histopathology. The median (interquartile range)
83 age of the 419 was 37 (32-45) years and 278 (66%) were female. 322/419 participants had
84 positive staining while 2/419 were equivocal. There was no histological evidence of corneal
85 toxicity. Mild discomfort was reported by 88 (21%) and mild superficial punctate keratopathy
86 seen in 7 (1.7%). For detecting OSSN, Toluidine blue had a sensitivity of 92% (95%CI, 87%-
87 96%), specificity 31% (95%CI, 25%-36%), positive predictive value 41% (95%CI, 35%-46%),
88 and negative predictive value 88% (95%CI, 80%-94%). Inter-observer agreement was
89 substantial for staining ($k=0.8$) and moderate for diagnosis ($k=0.4$).

90

91 CONCLUSION AND RELEVANCE

92 With the high sensitivity and low specificity for OSSN compared with histopathology among
93 patients with conjunctival lesions, Toluidine Blue 0.05% vital staining is a good screening
94 tool, but not a good diagnostic tool due to a high frequency of false positives. The high
95 negative predictive value suggests that a negative staining result indicates that OSSN is
96 relatively unlikely.

97

98

99

100 **Background**

101 Ocular surface squamous neoplasia (OSSN) is an aggressive eye cancer, particularly
102 affecting young adults in Africa, causing visual disability, high morbidity and mortality. The
103 diagnosis is problematic. In most African countries pathology services are limited; most
104 clinicians depend on their clinical judgment.^{1, 2} However, the appearance of OSSN overlaps
105 with several benign conditions making a clinical impression unreliable. Surgical excision is
106 the mainstay of OSSN treatment. A simple diagnostic test would help clinicians plan
107 management, for example, by better delineating the boundaries of the lesion during excision.
108 The test may also help in distinguishing early recurrent tumour from non-malignant abnormal
109 tissue such as fibrosis, possibly avoiding the need for additional surgery.

110

111 Vital stains are used to colour living tissues. Several dyes are used extensively in ophthalmic
112 surgery.^{3, 4} Toluidine blue (ToB) is an acidophilic metachromatic dye that stains abnormal
113 tissue dark royal blue by penetrating into the nuclei of cancerous cells where it has a
114 selective affinity for nucleic acids and by accumulating in the intercellular spaces.⁵ Malignant
115 tissues stain more frequently than healthy epithelia because of their abundant nuclear
116 material from increased mitoses and poor cell-to-cell adhesion.^{6, 7} Mucin and inflammatory
117 cells also take up ToB.^{5, 7} ToB has been used safely for many years to aid the clinical
118 diagnosis of oral and oropharyngeal cancer and to demarcate tumours during surgical
119 excision.^{8, 9}

120

121 A case report from Japan described the first use of topical ToB 0.05% vital staining for
122 OSSN.¹⁰ The dye was reported to clearly demarcate the abnormal tissue, assisting the
123 excision. The authors commented that ToB did not stain other conjunctival lesions such as
124 pterygium (no data presented) and it was not toxic to the ocular surface. Two relatively small
125 studies recently evaluated vital staining for OSSN using ToB 1% in Brazil and methylene
126 blue 1% in South Africa.^{11, 12} However, given the variation in clinical phenotype and
127 prevalence of conjunctival lesions it is necessary to test this in the local setting.

128

129 The aim of this study was to investigate the utility of Toluidine Blue 0.05% solution in
130 detecting neoplastic tissue by evaluating its safety, accuracy and inter-observer variation.

131

132

133 **Methods**

134 *Ethical Approval*

135 This study was formally reviewed and approved by the Kenyatta National Hospital –
136 University of Nairobi Ethics and Research Committee (KNH-UON ERC) and the London
137 School of Hygiene and Tropical Medicine Ethics Committee. This study adhered to the
138 tenets of the Declaration of Helsinki. All participants gave informed written consent to take
139 part in the study before enrolment and did not receive a stipend to participate.

140

141 *Participants*

142 The study was conducted between July 2012 and July 2014 in four eye care centres in
143 different parts of Kenya; Kenyatta National Hospital in Nairobi the capital city, PCEA Kikuyu
144 Eye Unit in Central Kenya, Kitale District Hospital in the north Rift Valley and Sabatia Eye
145 Hospital in western Kenya bordering Lake Victoria. It was part of a larger project on the
146 epidemiology and management of OSSN in Kenya. These centres receive referral cases
147 from the surrounding hospitals.

148

149 Consecutive adult patients (at least 18 years of age) seen in these four eye clinics with
150 conjunctival lesions (first presentation or recurrence) suspected to be OSSN scheduled for
151 surgery who gave consent to participate in the study were included. Pregnant women and
152 breastfeeding mothers were excluded.

153

154 *Toluidine Blue Eye Drops*

155 Toluidine Blue 0.05% aqueous solution was prepared in the Kikuyu Eye Unit eye drop
156 production facility. Toluidine powder (Sigma Aldrich, UK) 0.05g was diluted in 100ml of
157 freshly distilled water and aliquoted into 5ml eye drop bottles. The bottles were sterilised in a
158 water bath at 98°C for 30 minutes and checked for particles. Any with particles was
159 discarded. A bottle was used for up to 28 days once opened. New batches were prepared
160 every 6 months.

161

162 *Clinical Assessment*

163 A comprehensive ophthalmic examination was conducted using a slit lamp. Clinical features
164 of lesions were assessed including inflammation, leukoplakia and involvement of adjacent
165 structures Vital staining with Toluidine Blue 0.05% solution was performed at the slit lamp
166 before surgery. One drop of the dye was applied to the ocular surface waiting for 30 seconds
167 before wiping off the excess spillover from the eyelids with a soft tissue paper. Topical
168 anaesthetic was not applied before staining in order to evaluate if ToB was painful. Staining
169 with fluorescein was not done to avoid interference with the ToB dye.

170

171 *Surgery and Histopathology*

172 All lesions were excised under infiltration local anaesthetic using an operating microscope
173 with a 3mm clear margin. The defect was reconstructed by primary closure. Cryotherapy
174 was not applied as the participants with OSSN were invited to enroll in an additional
175 treatment trial post-operatively. Specimens were placed directly into buffered formalin and
176 subsequently examined at the histopathology laboratory at the MP Shah Hospital, Nairobi.
177 One pathologist examined all the histology slides. Participants with mild, moderate or severe
178 conjunctival intraepithelial neoplasia (CIN I, II, III), carcinoma-in-situ (CIS) or invasive
179 squamous cell carcinoma (well, moderately and poorly differentiated) were classified as
180 having OSSN. The diagnosis of actinic keratosis was based on the presence of elastotic
181 stromal degeneration, acanthosis, hyperkeratosis and parakeratosis in the presence of

182 normal cellular polarity. By the accepted criteria for dysplasia, such lesions were classified
183 as CIN only if there was loss of polarity.

184

185 a) Safety study

186 There is extensive experience on the safety of using ToB in the oral cavity but only relatively
187 limited data on the eye.^{9, 11-14} Therefore, we conducted initial testing on large tumours
188 scheduled for exenteration. The exenteration specimens were examined by a
189 histopathologist for evidence of corneal toxicity such as necrosis or inflammatory cells and
190 dye penetration into the stroma (free or engulfed in macrophages).

191

192 The results of the safety data and information from previous published series were reported
193 to the ethics committee and permission was granted to extend testing to participants with
194 smaller lesions. Participants were asked about pain or discomfort, and we evaluated the
195 cornea at the slit lamp for epithelial changes such as punctate staining.

196

197 b) Accuracy study

198 Staining was recorded using a 5-point system as: none, equivocal (if it was too pale to be
199 sure there was staining), pale blue, mixed pattern (pale and deep blue) or deep royal blue
200 (Figure 1). For the purpose of analysis, any blue staining was considered positive and
201 equivocal staining excluded from the analysis. A stratified analysis by degree of staining was
202 also conducted. Since it would be unlikely that a clinician would be in doubt about the likely
203 diagnosis in patients with large orbital tumours, orbital cases were excluded from this
204 analysis. Staining (positive vs negative) was compared to histopathology (OSSN vs not
205 OSSN).

206

207 c) Inter-observer variation study

208 The eye was photographed before and about 30 seconds after staining for subsequent
209 independent grading of the staining pattern. A pair of photographs was taken, one in primary

210 gaze and the other with the lesion in the centre using a Nikon D90 digital camera with
211 105mm lens.

212

213 Six final year residents in the Department of Ophthalmology, University of Nairobi at
214 Kenyatta National Hospital were trained by one author (SG) using projected slides showing
215 different degrees of Toluidine blue staining. They were informed that previous studies
216 suggested that generally OSSN stained positive and benign lesions were negative, but this
217 may not be invariably the case. A week later the same group independently assessed
218 photographs from the last 100 consecutive participants enrolled into the study from one
219 centre. Cases with features that are highly suggestive of malignancy, such as very large
220 tumours invading the orbit were excluded. The trainer (SG) projected the images on a
221 screen. None of the slides had been shown in the training session. The residents were
222 masked to the diagnosis and did not discuss the cases. They were asked to grade the
223 staining and suggest a diagnosis (OSSN vs non-OSSN), taking into account the clinical
224 features of the lesion. The clinical case-mix in this sample of patients was comparable to the
225 whole dataset that included patients from all four study centres.

226

227 *Statistical Analysis*

228 Data was managed in Access (Microsoft Windows 2010) and transferred into STATA version
229 12.1 (StataCorp, College Station, Texas, USA) for analysis. Sensitivity, specificity and
230 predictive values of ToB vital staining were computed based on subsequent histological
231 diagnosis.

232

233 For the inter-observer component, the scores for each clinician were compared to a
234 reference standard using the kappa (κ) statistic and graded using the Landis & Koch
235 method.¹⁵ The examiners' staining score was compared to the lead author's assessment
236 while their clinical diagnosis was compared to the histopathology report. The proportions
237 they scored as positive or negative for stain and OSSN or non-OSSN for diagnosis were

238 reported. To calculate an average value, the kappa statistics for each grader were
239 transformed to Z scores using the Fisher Z transformation, averaged, and then back-
240 transformed to a kappa statistic.

241

242 **Results**

243 *Study Participants and Histological Diagnosis*

244 A STARD diagram is shown in **eFigure 1**. Five hundred and thirty-seven (537) participants
245 with conjunctival lesions were recruited to the larger OSSN project and 447 (83%)
246 underwent Toluidine blue staining. There were 90 people recruited into the larger study while
247 awaiting completion of the initial ToB safety phase. The final analysis consisted of 419
248 participants whose median (interquartile range) age was 37 (32-45) years and 277 (66%)
249 were female. There were 143 (34%) OSSN and 276 (66%) non-OSSN lesions (**Table 1**).

250

251 *a) Safety study*

252 Seven participants with very large tumours (all were squamous cell carcinoma) were
253 enrolled in the pilot toxicity study. None showed evidence of corneal toxicity on histology.
254 Seven participants out of the 419 (1.7%) had a mild superficial punctate keratopathy around
255 the lesion after vital staining possibly due to disruption of the tear film by the raised lesion
256 and the associated drying. These were distributed as follows; 4 pterygium, 1 carcinoma in
257 situ, 1 moderately differentiated squamous cell carcinoma and 1 capillary haemangioma.
258 Most participants tolerated the stain well; 88/419 (21%) reported some mild discomfort
259 immediately after application, all of which resolved rapidly.

260

261 *b) Accuracy study*

262 Different patterns and intensities of Toluidine Blue staining were seen (**Figure 1**). The seven
263 orbital tumours in the safety phase all stained deep royal blue. Two participants out of 419
264 showed equivocal staining and were removed from the analysis. One had moderate
265 intraepithelial dysplasia and the other a nevus.

266

267 Overall 322 of 417 (77%) smaller lesions stained with ToB, and staining was more frequent
268 in the OSSN group (Table 2). Any blue ToB staining had a high sensitivity (92%; 95%CI,
269 87%-96%), low specificity (31%; 95%CI, 25%-36%), high negative predictive value (88%;
270 95%CI, 80%-94%) and low positive predictive value (41%; 95%CI, 35%-46%) compared to
271 histology (Table 3). The low specificity was attributable to a high proportion (69.5%) of
272 benign lesions staining positive (65% of pterygia and 76% of actinic keratosis).

273

274 Deep royal blue staining demarcated the extent of the lesion well. A mixed staining pattern
275 was observed in which only parts of the lesion would stain particularly actinic keratosis
276 (Figure 1F). Mucus discharge also stained blue and should ideally be wiped away before
277 staining. Also 133/275 (48%) of benign lesions had leukoplakia which stained blue. Brown
278 pigmentation was found in 194 (47%) lesions. These included 12 cases of conjunctival
279 naevi. Pigmentation made interpretation of staining more difficult (Figure 1L).

280

281 *c) Inter-observer variation study*

282 Staining results were easy to interpret. The scores of the six graders were similar to the lead
283 author's (agreement 91.3%) (Table 4). The lead author found 79% of the lesions stained with
284 ToB, compared to an average of 76.5% for the six graders. The average kappa for staining
285 scores was substantial ($k=0.76$). The six graders scored more lesions as OSSN compared to
286 histopathology (53% vs 32%). The average kappa for diagnosis was moderate ($k=0.40$).

287

288

289 **Discussion**

290 This is the largest study to date to evaluate ocular surface vital staining for the diagnosis of
291 OSSN. It confirms findings from earlier studies that topical toluidine blue 0.05% is not
292 associated with any significant adverse effects and found that the large majority of OSSN

293 tumours stain.^{11, 12} The intensity of dark blue staining seen with the 0.05% preparation was
294 similar to 1% solutions reported in other studies in South Africa and Brazil.

295

296 There were minimal side effects of vital staining. The mild superficial punctate keratopathy
297 we observed may be attributable to dry eye due to disturbance of the tear film by the raised
298 lesion. Dry eye is the most common ocular surface manifestation of HIV with a prevalence of
299 up to 54%.^{16, 17} The mild discomfort reported on application of ToB may be aggravated by
300 dry eye syndrome. The use of topical anaesthetic before vital staining may prevent this.
301 Safety studies in animals found that intraocular injection (as opposed to topical use) of 1%
302 and 2% ToB caused irreversible damage to all the corneal layers; 0.5% damaged the
303 stromal keratocytes and corneal endothelium but 0.25% stained the lens capsule and did not
304 damage any corneal layer or the trabecular meshwork.¹⁸ Wander et al conducted animal
305 safety studies in rabbits and guinea pigs by applying eye drops of 0.01%, 0.1%, 0.25%,
306 0.5%, and 1.0% toluidine blue to stain corneal epithelial cells. The cells picked up the vital
307 dye within 5 minutes. Wash out time was rapid and no toxic effects were observed.¹⁹

308

309 The diagnostic accuracy results of our study are similar to the ones from Brazil and South
310 Africa showing high sensitivity and only low to moderate specificity (**Table 3**).^{11, 12} However,
311 our study indicates that the sensitivity and specificity may not be quite as high as the two
312 earlier, smaller studies had suggested. From the clinical standpoint however, the measure of
313 accuracy that is more important than sensitivity or specificity is the predictive value. The
314 positive predictive value in our study (41%) was lower than the South African (60%) and
315 Brazilian (73%) studies. A caveat to such comparison is that the estimates of predictive
316 values are only valid for the actual study population and similar populations with the same
317 disease prevalence.

318

319 The South African study had a similar patient profile to ours with regard to age, sex and HIV
320 infection.¹² However, there were some of key differences: they used Methylene blue 1% dye

321 and had a higher proportion of OSSN. Importantly, they combined the CIN lesions with
322 benign lesions in their analysis, while we classified all CIN as part of the OSSN spectrum.
323 They do not report how the CIN cases stained or whether there were different patterns of
324 staining (pale or mixed). The patients in the Brazilian study were older than the Kenyan and
325 South African study participants and were predominantly male (62%). Their HIV prevalence
326 was not reported. This probably reflects different patterns of disease. The classification of
327 OSSN and the grading systems for describing the staining in the Brazilian and Kenyan
328 studies were similar. However, in the Brazilian study the concentration of Toluidine blue (1%)
329 was 20 times that used in Kenya.

330

331 The differences observed in the test performance between these three studies could have a
332 number of explanations. Firstly, it may reflect the larger sample size. There could be
333 differences in patient populations, lesions included and diagnostic methods. We found lesion
334 pigmentation made it more difficult to be certain about staining. The other two studies do not
335 report on pigmentation. Our study had a higher proportion and wider variety of non-OSSN
336 lesions than the other two. In addition, the gold standard for diagnosis of OSSN,
337 histopathology, is open to interpretation.²⁰

338 ToB has a higher sensitivity and specificity for oral cancers than we observed in our study. A
339 Cochrane systematic review showed variable sensitivity of 50% to 97% and a more uniform
340 specificity of 98% to 99%.⁸ However the prevalence of disease varied widely (1.4% to
341 50.9%). The difference between ocular and oral performance of ToB is unclear. Oral rinsing
342 with 1% acetic acid before staining removes the surface debris (glycoprotein layer) and
343 dehydrates cells.²¹ This may remove keratotic surface plaques which stained deep blue in
344 our study (Figure 1). False positives may be further explained by the fact that ToB also
345 stains inflammatory cells and mucin.⁷ Also OSSN, pterygia and actinic keratosis may be on
346 the same causal pathway due to their association with ultraviolet radiation, p53 mutation and
347 HPV with some regarding actinic keratosis and pterygia as pre-malignant lesions.²²⁻²⁴ They
348 may therefore stain similarly.

349

350 The interpretation of staining results was relatively straightforward and had higher inter-
351 observer agreement ($k=0.76$) than clinical diagnosis ($k=0.40$). Clinical diagnosis is more
352 difficult due to the overlap in clinical features of OSSN and Non-OSSN.

353

354 This study had various limitations. Firstly, the concentration, purity and stability of ToB may
355 have changed over time once a bottle was opened. A rising concentration may have
356 increased the staining of all lesions. Secondly, in the analysis using 2x2 contingency tables,
357 staining is treated as a dichotomous variable while in fact there are different degrees of
358 intensity of blue staining. There was a high frequency of lesion pigmentation in this
359 population but the use of more concentrated ToB may be toxic given its cell nucleus entry
360 and may increase the false positive rates by staining more benign lesions.

361

362 If a test has a high sensitivity, a negative result has a high chance of ruling out the disease.²⁵
363 Toluidine blue had a high sensitivity so a negative result makes OSSN unlikely does not
364 completely rule it out.

365

366 In conclusion, ToB staining is safe and easily interpreted by different observers. Very few
367 OSSN lesions did not stain with ToB. If ToB staining is negative then OSSN is unlikely.
368 Positive staining demarcates conjunctival lesions well which could help in delineating the
369 surgical excision margin particularly for circumlimbal OSSN lesions where both the corneal
370 and conjunctival extents would otherwise not be clearly seen. Staining also detected small
371 recurrences of OSSN (eFigure 2). ToB vital staining would not replace histopathology. The
372 high sensitivity and low specificity makes ToB a good screening tool where there is an
373 important penalty for missing a disease. In populations with limited histopathology services,
374 an algorithm combining ToB staining with other clinical features may raise the composite
375 specificity for OSSN.

376

377 **Acknowledgments:**

378 The authors have no conflict of interest disclosures. SG received funding from the British
379 Council for Prevention of Blindness (BCPB) fellowship programme. MJB is supported by The
380 Wellcome Trust (Grant Number 098481/Z/12/Z). The funding organizations had no role in
381 the design or conduct of this research. SG and MJB had full access to all the data in the
382 study and take responsibility for the integrity of the data and the accuracy of the data
383 analysis.

384

385 **Author contributions:**

386 *Study concept and design:* Gichuhi, Jaoko, Sagoo, Weiss, Burton

387 *Acquisition, analysis, or interpretation of data:* All authors

388 *Drafting of the manuscript:* Gichuhi, Sagoo, Weiss, Burton

389 *Critical revision of the manuscript for important intellectual content:* All authors

390 *Statistical analysis:* Gichuhi, Weiss, Burton

391 *Obtained funding:* Gichuhi, Weiss, Burton

392 *Administrative, technical, or material support:* Macharia, Kabiru, Zindamoyen, Rono,

393 Ollando, Wanyonyi, Wachira, Munene, Jaoko, Sagoo, Weiss, Burton

394 *Study supervision:* Burton, Weiss

395

396 **Conflict of interest disclosures:**

397 All authors have completed and submitted the ICMJE Form for Disclosure of Potential
398 Conflicts of Interest and none were reported.

399

References

- 400 1. Adesina A, Chumba D, Nelson AM, et al. Improvement of pathology in sub-Saharan Africa.
401 *Lancet Oncol.* Apr 2013;14(4):e152-157.
- 402 2. Rambau PF. Pathology practice in a resource-poor setting: Mwanza, Tanzania. *Arch Pathol*
403 *Lab Med.* Feb 2011;135(2):191-193.
- 404 3. Rodrigues EB, Costa EF, Penha FM, et al. The use of vital dyes in ocular surgery. *Surv*
405 *Ophthalmol.* Sep-Oct 2009;54(5):576-617.
- 406 4. Haritoglou C, Yu A, Freyer W, et al. An evaluation of novel vital dyes for intraocular surgery.
407 *Invest Ophthalmol Vis Sci.* Sep 2005;46(9):3315-3322.
- 408 5. Herlin P, Marnay J, Jacob JH, Ollivier JM, Mandard AM. A study of the mechanism of the
409 toluidine blue dye test. *Endoscopy.* Jan 1983;15(1):4-7.
- 410 6. Gandolfo S, Pentenero M, Broccoletti R, Pagano M, Carrozzo M, Scully C. Toluidine blue
411 uptake in potentially malignant oral lesions in vivo: clinical and histological assessment. *Oral*
412 *Oncol.* Jan 2006;42(1):89-95.
- 413 7. Sridharan G, Shankar AA. Toluidine blue: A review of its chemistry and clinical utility. *J Oral*
414 *Maxillofac Pathol.* May 2012;16(2):251-255.
- 415 8. Walsh T, Liu JL, Brocklehurst P, et al. Clinical assessment to screen for the detection of oral
416 cavity cancer and potentially malignant disorders in apparently healthy adults. *Cochrane*
417 *Database Syst Rev.* 2013;11:CD010173.
- 418 9. Patton LL, Epstein JB, Kerr AR. Adjunctive techniques for oral cancer examination and lesion
419 diagnosis: a systematic review of the literature. *J Am Dent Assoc.* Jul 2008;139(7):896-905;
420 quiz 993-894.
- 421 10. Kaji Y, Hiraoka T, Oshika T. Vital staining of squamous cell carcinoma of the conjunctiva using
422 toluidine blue. *Acta Ophthalmol Scand.* Dec 2006;84(6):825-826.
- 423 11. Romero IL, Barros Jde N, Martins MC, Ballalai PL. The use of 1% toluidine blue eye drops in
424 the diagnosis of ocular surface squamous neoplasia. *Cornea.* Jan 2013;32(1):36-39.
- 425 12. Steffen J, Rice J, Lecuona K, Carrara H. Identification of ocular surface squamous neoplasia
426 by in vivo staining with methylene blue. *Br J Ophthalmol.* Jan 2014;98(1):13-15.
- 427 13. Rashid A, Warnakulasuriya S. The use of light-based (optical) detection systems as adjuncts
428 in the detection of oral cancer and oral potentially malignant disorders: a systematic review.
429 *J Oral Pathol Med.* Sep 3 2014.
- 430 14. Allegra E, Lombardo N, Puzzo L, Garozzo A. The usefulness of toluidine staining as a
431 diagnostic tool for precancerous and cancerous oropharyngeal and oral cavity lesions. *Acta*
432 *Otorhinolaryngol Ital.* Aug 2009;29(4):187-190.
- 433 15. Landis JR, Koch GG. The measurement of observer agreement for categorical data.
434 *Biometrics.* Mar 1977;33(1):159-174.
- 435 16. Lestari YD, Sitompul R, Edwar L, Djoerban Z. Ocular diseases among HIV/AIDS patients in
436 Jakarta, Indonesia. *Southeast Asian J Trop Med Public Health.* Jan 2013;44(1):62-71.
- 437 17. Bekele S, Gelaw Y, Tessema F. Ocular manifestation of HIV/AIDS and correlation with CD4+
438 cells count among adult HIV/AIDS patients in Jimma town, Ethiopia: a cross sectional study.
439 *BMC Ophthalmol.* 2013;13(1):20.
- 440 18. Gamal Eldin SA, el Mehelmy EM, el Shazli EM, Mostafa YM. Experimental staining of the
441 anterior lens capsule in albino rabbits. *J Cataract Refract Surg.* Sep 1999;25(9):1289-1294.
- 442 19. Wander AH, Neumeister RD, Tschismadia I, Choromokos EA, Masukawa T. In vivo corneal
443 and conjunctival epithelial nuclear stain. *Cornea.* 1985;4(1):8-13.
- 444 20. Margo CE, Harman LE, Mulla ZD. The reliability of clinical methods in ophthalmology. *Surv*
445 *Ophthalmol.* Jul-Aug 2002;47(4):375-386.
- 446 21. Lingen MW, Kalmar JR, Karrison T, Speight PM. Critical evaluation of diagnostic aids for the
447 detection of oral cancer. *Oral Oncol.* Jan 2008;44(1):10-22.

- 448 **22.** Gichuhi S, Ohnuma SI, Sagoo MS, Burton MJ. Pathophysiology of ocular surface squamous
449 neoplasia. *Exp Eye Res.* Dec 2014;129C:172-182.
- 450 **23.** Liu T, Liu Y, Xie L, He X, Bai J. Progress in the pathogenesis of pterygium. *Curr Eye Res.* Dec
451 2013;38(12):1191-1197.
- 452 **24.** Di Girolamo N. Association of human papilloma virus with pterygia and ocular-surface
453 squamous neoplasia. *Eye (Lond).* Feb 2012;26(2):202-211.
- 454 **25.** Straus SE, Richardson WS, Glasziou P, Haynes BR. *Evidence-based medicine - how to practice
455 and teach EBM.* 3rd ed: Elsevier, Churchill Livingstone; 2005.

456

457

458 **Figure title and legend**

459 **Figure 1. Toluidine blue 0.05% staining intensities and patterns; a 5-point scale.**

460

461 The pictures in the left column show the lesions before staining and on the right after staining.

462

463

464

465

466

467

468 **Table 1. Toluidine blue staining patterns of 418 conjunctival lesions**

Histopathology	Staining result					Total
	None No. (%)	Pale blue No. (%)	Mixed No. (%)	Dark royal blue No. (%)	Equivocal No. (%)	
OSSN	11 (7.7)	23 (16.2)	17 (11.9)	91 (64.1)	1 (0.7)	143
Pterygium	55 (34.8)	24 (15.2)	31 (19.6)	48 (30.4)	0 (0)	158
Actinic Keratosis	20 (23.8)	15 (17.9)	19 (22.6)	30 (35.7)	0 (0)	84
Nevus	4 (33.3)	1 (8.3)	4 (33.3)	2 (16.7)	1 (8.3)	12
Squamous papilloma	1 (10.0)	4(40.0)	1(10.0)	4 (40.0)	0 (0)	10
Pyogenic granuloma	2 (66.7)	0 (0)	0 (0)	1 (33.3)	0 (0)	3
Haemangioma	0 (0)	0 (0)	0 (0)	2 (100.0)	0 (0)	2
Ocular rhinosporidiosis	0 (0)	0 (0)	0 (0)	2 (100.0)	0 (0)	2
Chronic conjunctivitis	0 (0)	0 (0)	1 (50)	1 (50)	0 (0)	2
Epidermoid cyst	0 (0)	0 (0)	0 (0)	1 (100)	0 (0)	1
Sarcomatoid spindle cell tumour ^a	1 (100.0)	0 (0)	0 (0)	0 (0)	0 (0)	1
Sebaceous hyperplasia of the caruncle	1 (100.0)	0 (0)	0 (0)	0(0)	0 (0)	1
Total	95 (22.5)	67 (16.0)	73 (17.5)	182 (43.5)	2 (0.5)	419

469 Abbreviations: OSSN, ocular surface squamous neoplasia

470 ^a this was a non-OSSN malignancy

471

472

473

474

475 **Table 2. The association between vital staining with Toluidine Blue 0.05% and**
 476 **histological category (OSSN or Not OSSN).**

Staining result	OSSN n(%)	Not OSSN n(%)	Total	OR (95% CI)	p-value
Any blue staining	131 (92.3%)	191 (69.5%)	322	5.2 (2.6-10.4)	<.001
No staining	11 (7.8%)	84 (30.6%)	95	1.0	-
Total	142 (100.0%)	275 (100.0%)	417 ^a		

Stratified analysis					
Dark royal blue	91 (64.1%)	91 (33.1%)	182	7.6 (3.6-16.2)	<.001
Pale blue	23 (16.2%)	44 (16.1%)	67	4.0 (1.7-9.3)	<.001
Mixed pattern ^b	17 (12.0%)	56 (20.4%)	73	2.3 (1.0-5.4)	.04
Not staining	11 (7.8%)	84 (30.6%)	95	1.0	-
Total	142 (100.0%)	274 (100.0%)	417		

477 Abbreviations: OSSN, ocular surface squamous neoplasia; OR, odds ratio
 478 ^a The 2 participants who had equivocal staining results in table 1 are excluded from this table
 479 ^b Some areas of the lesion were deep royal blue and others pale
 480 Individual percentages may have a rounding error

481 **Table 3. Test performance indices for various levels of toluidine blue vital staining and a comparison of this Kenyan study with**
 482 **studies from South Africa¹² and Brazil¹¹.**

Staining result	Sensitivity (95%CI)	Specificity (95%CI)	Positive predictive value (95%CI)	Negative predictive value (95%CI)	Area under the ROC curve (95%CI)
Any blue (dark, pale or mixed)	92% (87% - 96%)	31% (25% - 36%)	41% (35% - 46%)	88% (80% - 94%)	.61 (.58 - .65)
Dark royal blue or pale blue	80% (73% - 87%)	51% (45% - 57%)	46% (40% - 52%)	83% (77% - 89%)	.66 (.61 - .70)
Dark royal blue	64% (56% - 72%)	67% (61% - 72%)	50% (43% - 58%)	78% (72% - 83%)	.66 (.61 - .70)
Pale blue	16% (11% - 23%)	84% (79% - 88%)	34% (23% - 47%)	66% (61% - 71%)	.50 (.46 - .54)
Mixed pattern ^a	12% (7% - 19%)	80% (74% - 84%)	23% (14% - 35%)	64% (58% - 69%)	.46 (.42 - .49)

Comparison with other studies			
Parameter	Kenya	S. Africa	Brazil ^b
Vital stain dye	toluidine blue 0.05%	methylene blue 1%	toluidine blue 1%
Number of participants	419	75	47
Gender, Female No. (%)	277 (66)	45 (60)	18 (38)
Age, median (IQR), y	37 (32-45)	35 ^c	58 ^c
OSSN prevalence by histopathology No. (%)	142 (34)	33 (44) ^d	27 (57)
Sensitivity (95%CI)	92% (87% - 96%)	97% (85% - 100%)	100% (87% - 100%)
Specificity (95%CI)	31% (25% - 36%)	50% (36% - 65%)	50% (27% - 73%)
Positive predictive value (95%CI)	41% (35% - 46%)	60% (47% - 72%)	73% (56% - 86%)
Negative predictive value (95%CI)	88% (80% - 94%)	95% (78% - 99%)	100% (69% - 100%)

483 Abbreviations: ROC, receiver operator characteristic; IQR, interquartile range

484 ^a Some areas of the lesion were deep royal blue and others pale

485 ^b intervals were calculated from the data presented in the paper

486 ^c The interquartile range was not reported in S. Africa and Brazil.

487 ^d In the South African study, 49 (65%) were on the OSSN spectrum, however, in the analysis that was presented CIN was combined in with benign lesions for the calculation of the test parameters.

488

489

490

491

492

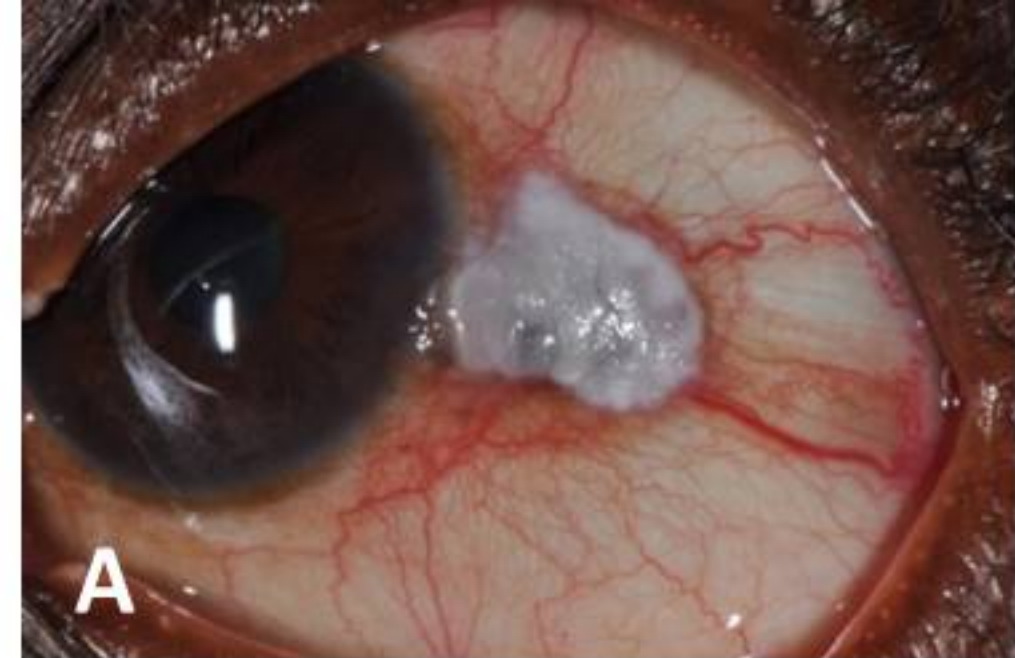493 **Table 4. Inter-observer agreement for the evaluation of ToB staining in 100 patients**

Feature	Reference Standard No. (%)	Six Graders Median %	Agreement Median %	Average Kappa k (95%CI)^c
Staining result ^a				
Positive	79 (79.0)	76.5%	91.3%	0.76 (0.68 - 0.82)
Negative	21 (21.0)	23.5%		
Diagnosis ^b				
OSSN	32 (32.0)	53.0%	70.7%	0.40 (0.31 - 0.48)
Non-OSSN	68 (68.0)	47.0%		

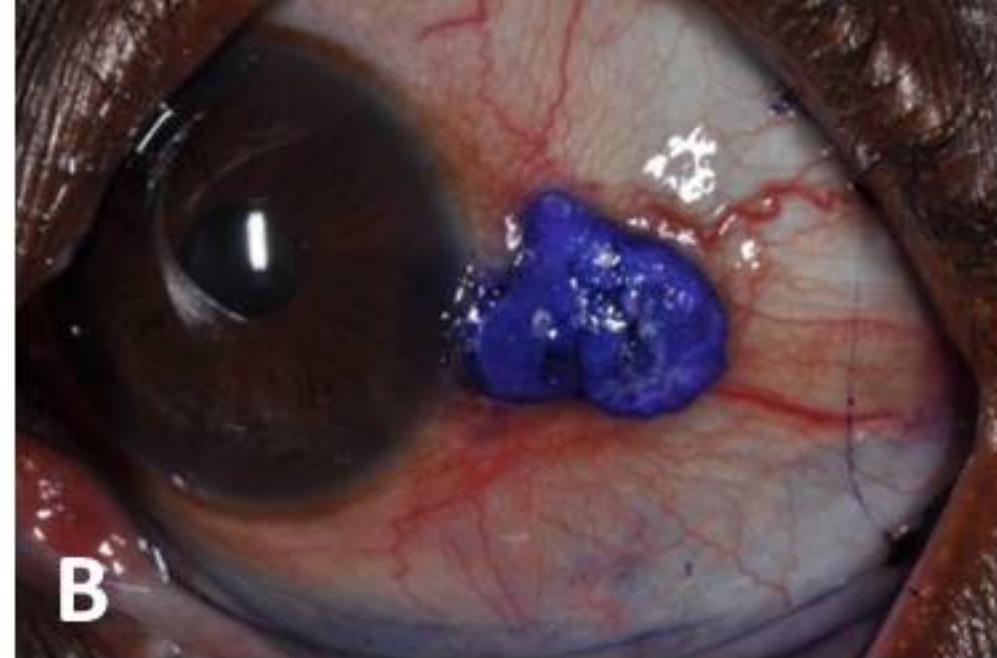
494 ^a The reference standard for staining was the lead author

495 ^b The reference standard for diagnosis was the histopathology result

496 ^c The average kappa statistic was obtained by transforming the kappa statistics for each grader to Z scores using the Fisher Z
497 transformation, averaging and performing a back-transformation.

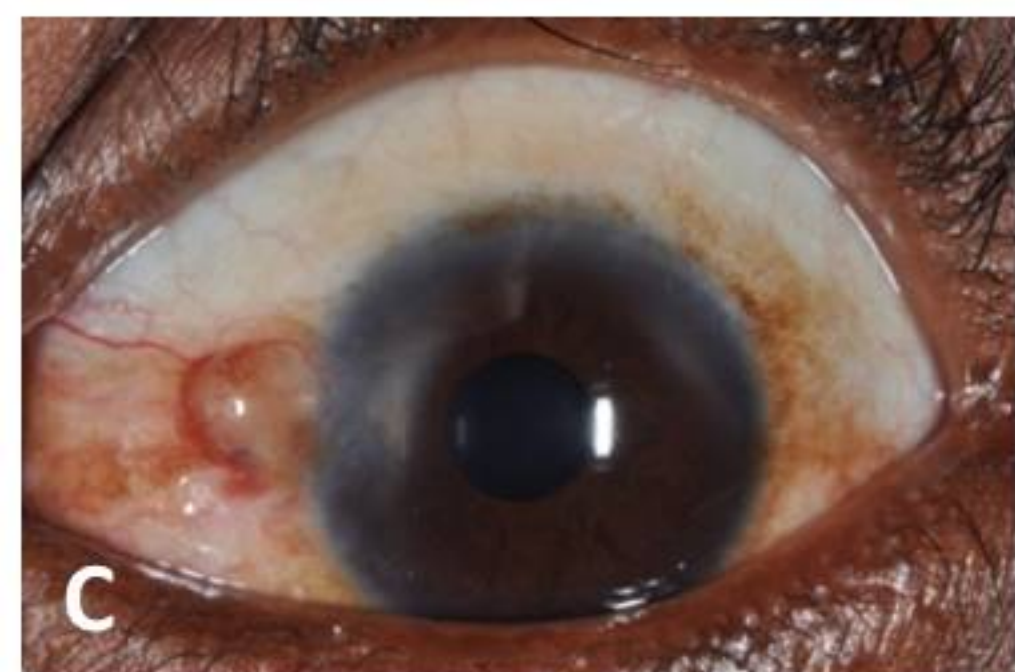


A

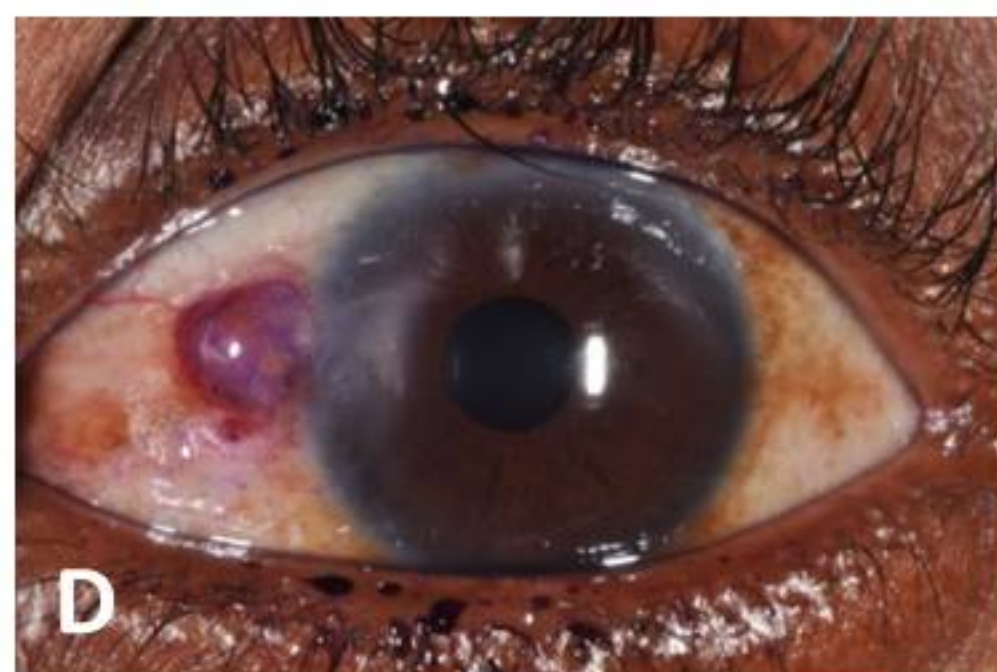


B

Dark royal blue

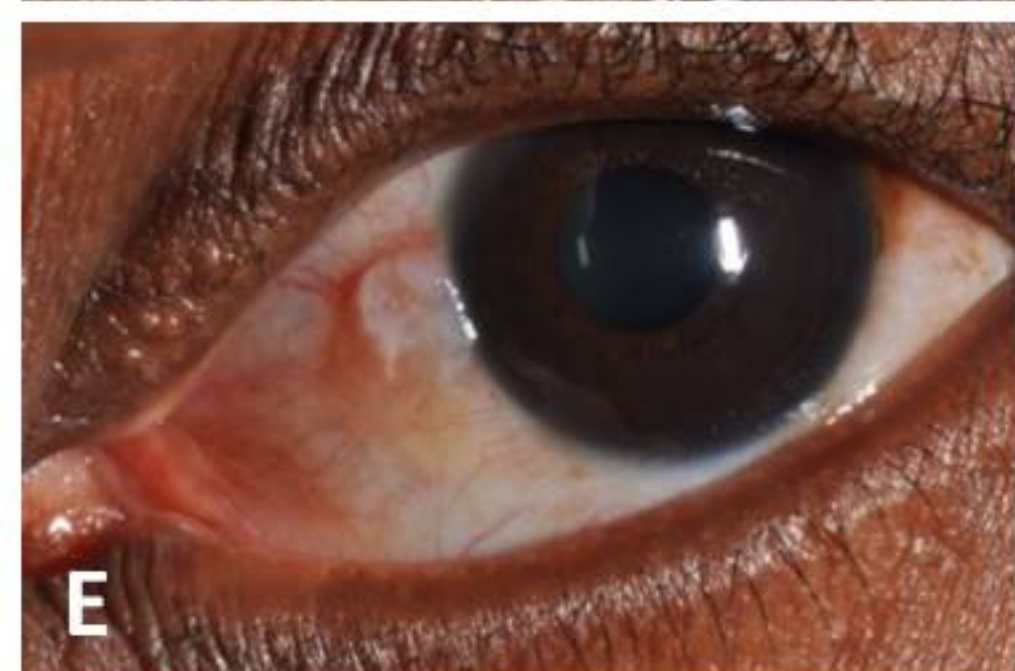

C

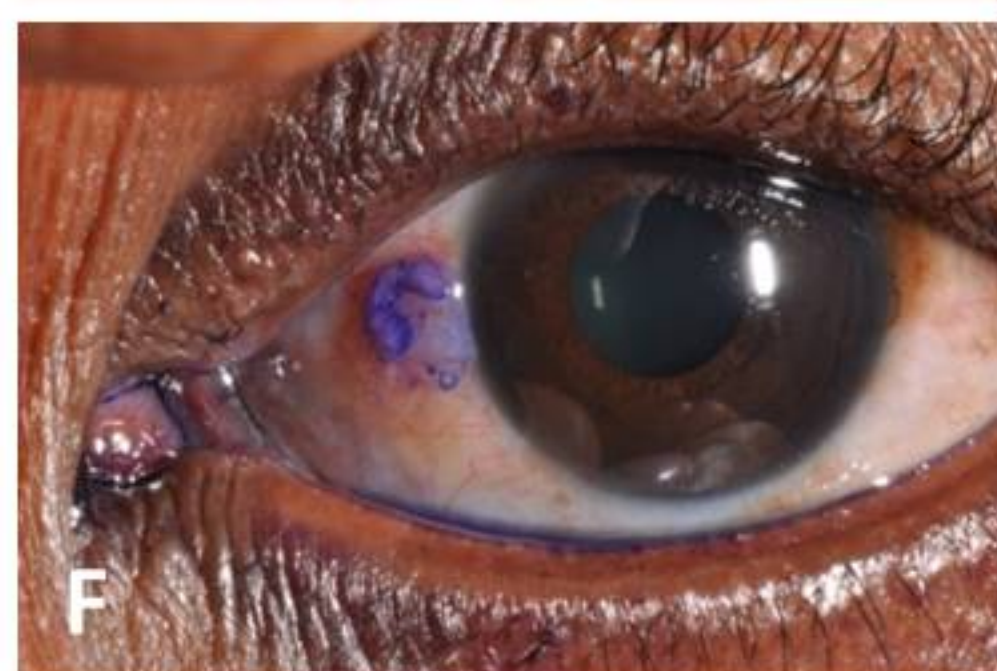


D

Pale blue

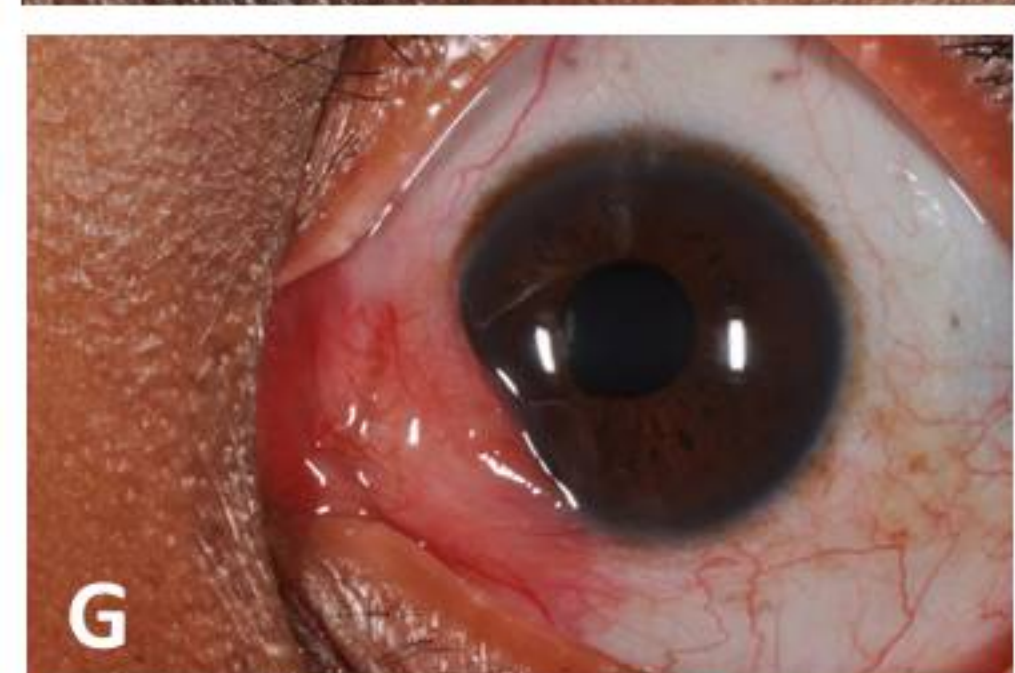

E

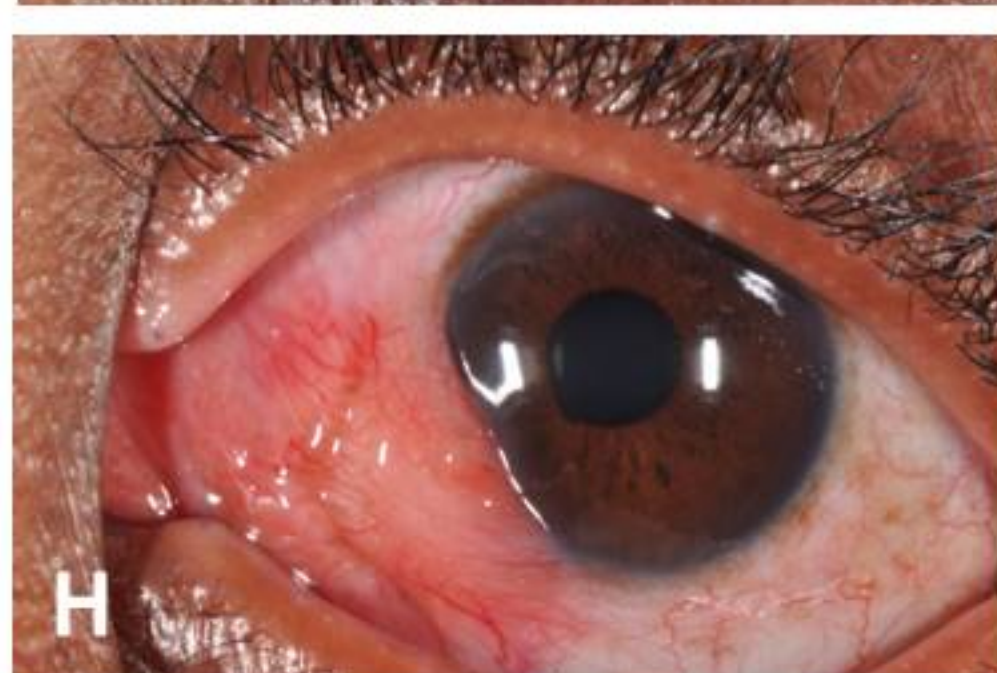

F

Mixed staining
(some parts of
the lesion stain
dark royal blue,
some pale and
others do not
stain)

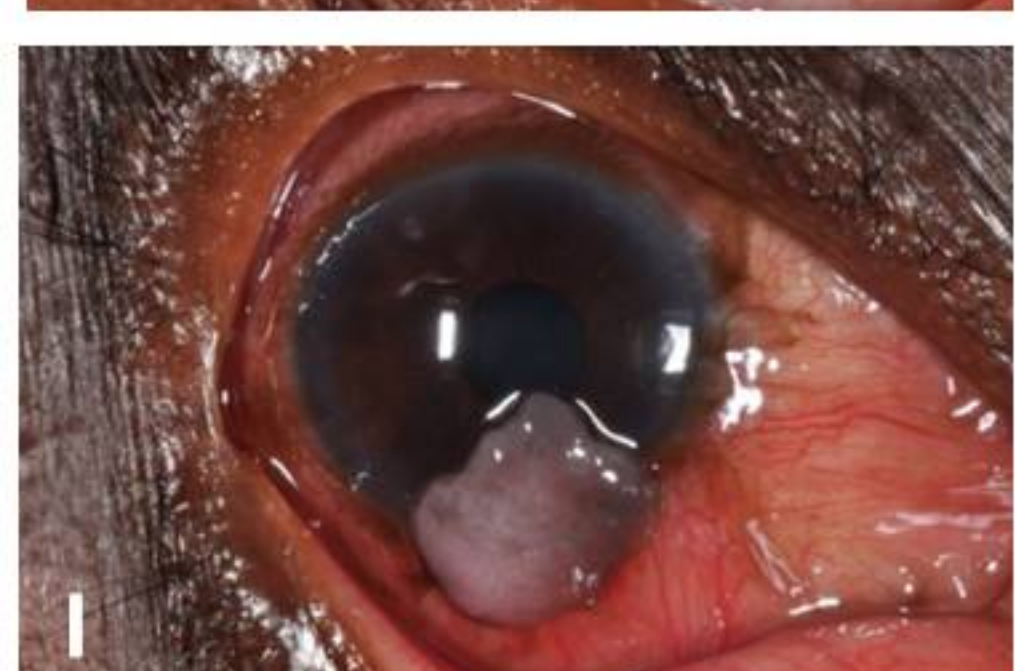


G

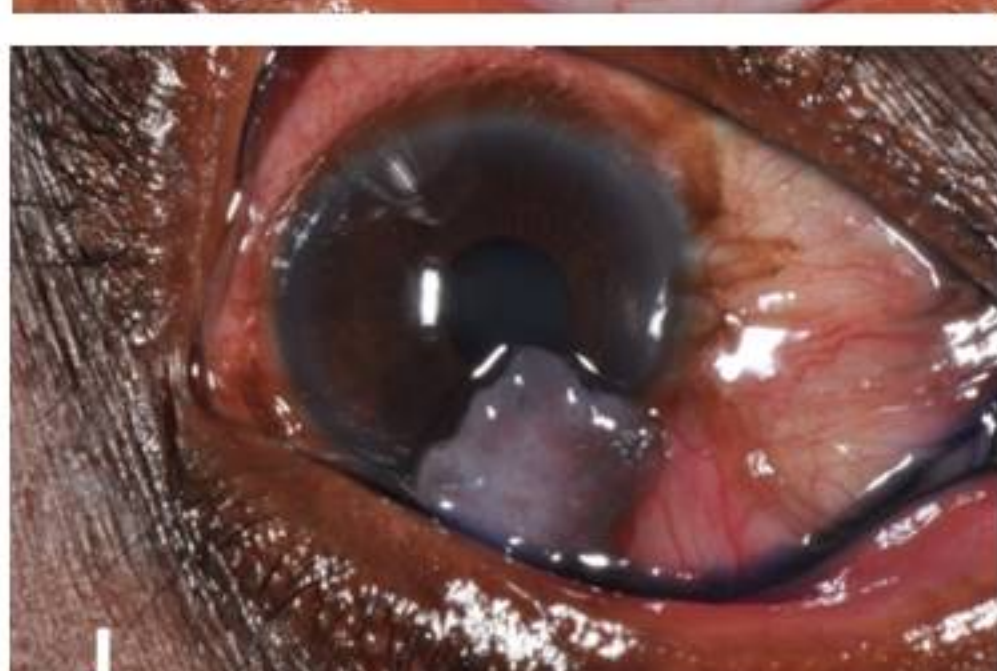


H

None

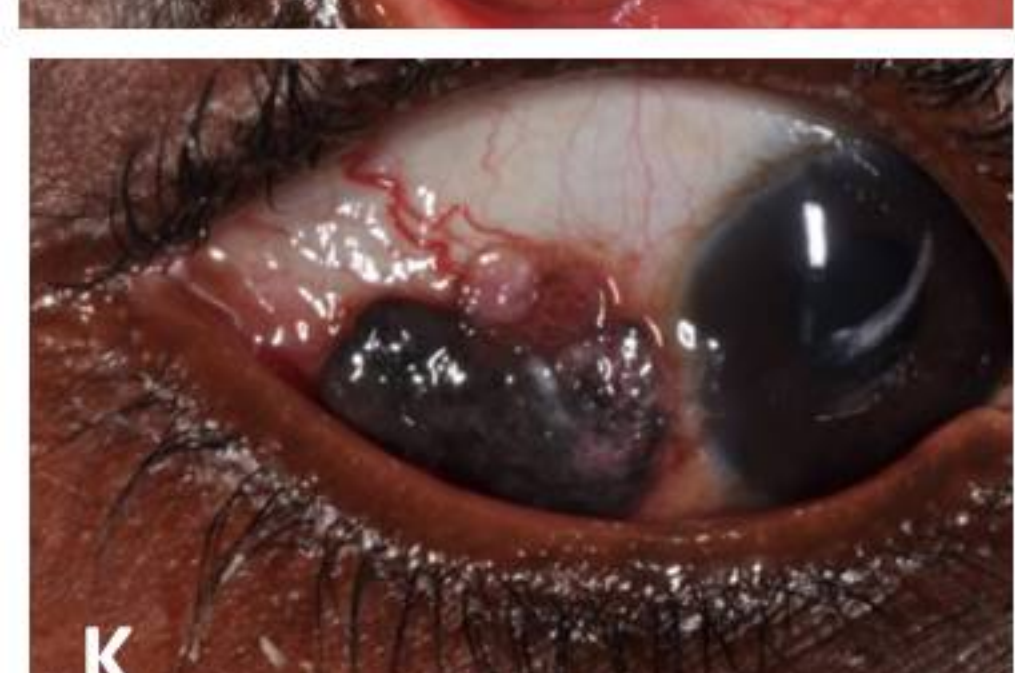

I

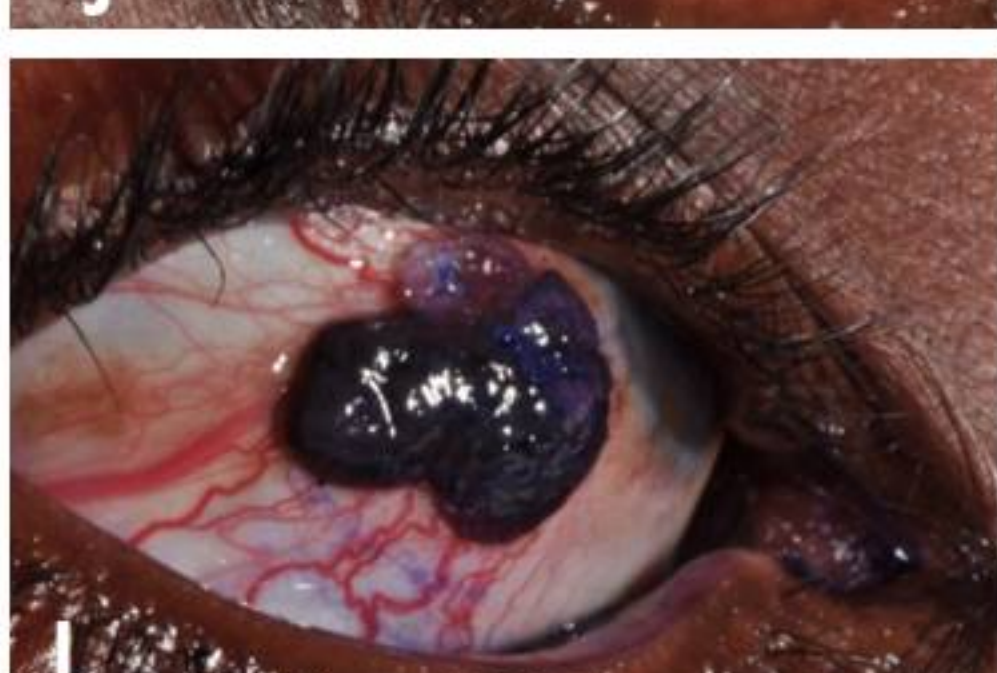

J

Equivocal



K



L

NOTE:
Brown
pigmentation
may make it
difficult to
interpret as the
staining may
be obscured