

LONDON
SCHOOL of
HYGIENE
& TROPICAL
MEDICINE



LSHTM Research Online

Hu, VH; Massae, P; Weiss, HA; Cree, IA; Courtright, P; Mabey, DC; Bailey, RL; Burton, MJ; (2010)
In Vivo Confocal Microscopy of Trachoma in Relation to Normal Tarsal Conjunctiva. *Ophthalmology*.
ISSN 0161-6420 DOI: <https://doi.org/10.1016/j.optha.2010.08.029>

Downloaded from: <http://researchonline.lshtm.ac.uk/2225/>

DOI: <https://doi.org/10.1016/j.optha.2010.08.029>

Usage Guidelines:

Please refer to usage guidelines at <https://researchonline.lshtm.ac.uk/policies.html> or alternatively contact researchonline@lshtm.ac.uk.

Available under license: <http://creativecommons.org/licenses/by-nc-nd/2.5/>

<https://researchonline.lshtm.ac.uk>

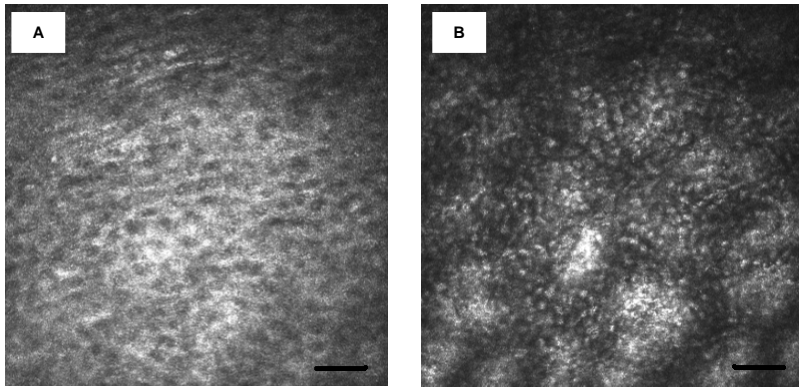


Figure 9. Lid margin epithelium. Images are 400×400µm with the bar representing 50µm. **A**, superficial epithelium. **B**, deeper epithelium.