

LONDON
SCHOOL of
HYGIENE
& TROPICAL
MEDICINE



LSHTM Research Online

Hulsman, Niels; van der Meulen, Jan; Talacua, Hanna; Essoussi, Bachir; Hermanns, Henning; (2020) Clot Formation in Cardiopulmonary Bypass Circuit After Application of Factor XI Concentrate. *Journal of Cardiothoracic and Vascular Anesthesia (JCVA)*, 34 (8). pp. 2178-2180. ISSN 1053-0770
DOI: <https://doi.org/10.1053/j.jvca.2020.02.013>

Downloaded from: <https://researchonline.lshtm.ac.uk/id/eprint/4673212/>

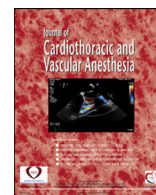
DOI: <https://doi.org/10.1053/j.jvca.2020.02.013>

Usage Guidelines:

Please refer to usage guidelines at <https://researchonline.lshtm.ac.uk/policies.html> or alternatively contact researchonline@lshtm.ac.uk.

Available under license. To note, 3rd party material is not necessarily covered under this license: <http://creativecommons.org/licenses/by-nc-nd/3.0/>

<https://researchonline.lshtm.ac.uk>



Case Report

Clot Formation in Cardiopulmonary Bypass Circuit After Application of Factor XI Concentrate

Niels Hulsman, MD^{*,1}, Jan van der Meulen, MD[†],
Hanna Talacua, MD[†], Bachir Essoussi, MSc[†],
Henning Hermanns, MD^{*}

^{*}Department of Anesthesiology, Amsterdam UMC, University of Amsterdam, Amsterdam, The Netherlands

[†]Department of Cardiothoracic Surgery, Amsterdam UMC, University of Amsterdam, Amsterdam, The Netherlands

Key Words: Extracorporeal circulation; cardiopulmonary bypass; hemophilia C; factor XI deficiency; FXI concentrate

THE MANAGEMENT of inherited or acquired coagulation disorders can be challenging during cardiac surgery with extracorporeal circulation. Although guidelines recommend preoperative supplementation of factor XI (FXI) with severe hemophilia C, there are certain risks involved with this strategy with the application of cardiac bypass.

Clinical Summary

A 60-year-old patient was scheduled for CABG after suffering from symptomatic angina pectoris. His medical history included severe FXI deficiency (activity 1%), hypertension, and colitis ulcerosa. He did not report a significant bleeding history other than bleeding complication after tooth extraction. His tonsillectomy was uneventful. Specific laboratory results include factor IX 148% (50-150), FXI <5% (50-150), and factor XII 138% (50-150). The baseline activated partial thromboplastin time was 115 seconds, which could be corrected after mixing with normal serum to 290 seconds. Treatment with double antiplatelet therapy had been started after the diagnosis of non-ST-elevation myocardial infarction. Along with acetylsalicylic acid, his clopidogrel was continued during surgery. Preoperatively, the hematologist was consulted and pretreatment with FXI concentrate

isolated from human plasma (Hemoleven) was advised. The recommended dose was 30 IU/kg to increase the activity of FXI above the 50% for major surgery. On the day of surgery, 60 minutes before incision and approximately 150 minutes before initiation of the cardiopulmonary bypass (CPB), the patient was treated with 2.000 IU of Hemoleven by an adjusted body weight of 67 kg. Hereafter, FXI activity increased to 59% and his activated partial thromboplastin time decreased from 115 to 34 seconds with no significant effect on the activated clotting time (ACT) (from 96 seconds before to 99 seconds after treatment). A 10-mg/kg bolus of tranexamic acid was given followed by continuous infusion of 2 mg/kg/h until the end of surgery. After sternotomy and preparation of the left internal mammary artery, 22.500 IU of heparin were administered (plus 10.000 IU of pump priming). Five minutes hereafter, the ACT was prolonged to 356 seconds, whereupon additional 10.000 IU of heparin were given. The second ACT was measured at 445 seconds and because local protocol demands an ACT of at least 450 seconds, another 10.000 IU of heparin were administered. Finally, ACT was 568 seconds, extracorporeal circulation was initiated within 10 minutes, and surgery was continued. After 15 minutes on cardiopulmonary bypass, during the anastomosis of the venous bypass on the posterior descending artery, blood clots appeared in the venous blood reservoir (Fig 1) and oxygenator (Fig 2). The decision was made to urgently wean the patient from the extracorporeal circulation and accomplish the remaining bypasses (left internal mammary artery on left anterior descending and venous graft on the posterolateral artery) off

¹Address reprint requests to: Niels Hulsman, MD, Department of Anaesthesiology, Amsterdam UMC, University of Amsterdam, Meibergdreef 9, Amsterdam, The Netherlands.

E-mail address: n.hulsman@amsterdamumc.nl (N. Hulsman).



Fig. 1. Visible clots in the reservoir of the cardiopulmonary bypass circuit.

pump. After revascularization, heparin was partially antagonized with 15,000 IU of protamine, resulting in an ACT of 166 seconds. During surgery, 2 units of red blood cells were administered. In the intensive care unit, a patient was treated with additional 7,000 IU of protamine because of excessive blood loss from the wound drains, after which blood loss decreased substantially. On day 1, the patient was transferred from the intensive care unit to the ward. On day 3, FXI levels decreased to 11%. The patient was discharged from the hospital on day 4 after receiving 1,000 IU of Hemoleven, which, in turn, increased FXI level to 22%. There were no thrombotic complications reported in the postoperative period and after discharge to home.

Discussion

FXI deficiency is an autosomal recessive congenital disease affecting 1:1,000,000 persons in the normal population but has a high prevalence under certain ethnic groups such as the Ashkenazi Jewish population (9%). In contrast to FVIII (hemophilia A) and FIX deficiency (hemophilia B), FXI deficiency is a mild bleeding disorder without major consequences in normal life. Yet, in case of surgery or trauma, severe bleeding complications can occur, especially when tissue is involved with high fibrinolytic activity.¹ Interestingly, FXI deficiency also is associated with decreased incidence of cardiovascular events and venous thromboembolism.²

FXI deficiency can be caused by a decreased activity of FXI owing to a decreased level of FXI or the presence of a FXI inhibitor. Recommendations for perioperative treatment include antifibrinolytic therapy and preoperative administration of fresh frozen plasma or FXI concentrate in case of decreased level of FXI. Target activity for FXI is 40% to 50% for minor surgery and 60% to 70% for major surgery.³ If a FXI inhibitor is present, FXI supplementation is not beneficial and successful management in case of FXI inhibitor has been achieved with low dose recombinant FVIIa and antifibrinolytics.⁴



Fig. 2. Visible clots in the oxygenator of the cardiopulmonary bypass circuit.

To the authors' knowledge, this is the first case report of a serious complication during extracorporeal circulation after preoperative administration of FXI concentrate despite adequate heparin treatment. There are several reports of arterial thrombosis or venous thromboembolic complication after treatment with FXI concentrate, some of which were fatal, however not in cardiac surgery.^{5,6} There is one report on an uneventful aortic valve replacement in which the patient received 1,000 IU of Hemoleven preoperatively.⁷ In the authors' case, the patient was treated with 2,000 IU of Hemoleven, resulting in a FXI activity of 59%. This value is considered adequate without increased thrombotic risk. After ruling out other causes such as medication errors like inadvertent administration of protamine, the administration of FXI concentrate is, in the authors' view, the most likely cause of the excessive clot formation in the extracorporeal circuit, although there is no data to confirm this hypothesis. A safer approach might be to correct FXI after separation from extracorporeal circulation in case of clinically relevant coagulopathy. Furthermore, perioperative correction of FXI deficiency with FXI concentrate and recombinant FVIIa seems to bear a higher risk of thromboembolic complications compared with other strategies, such as factor 8 inhibitor bypassing activity, fresh frozen plasma, desmopressin, or tranexamic acid.³ Additionally, addition of FXI in deficient blood can produce a laboratory hematology picture

suggestive of consumptive coagulopathy or disseminated intravascular coagulopathy.^{8,9}

The presence of coagulation factor deficiency in patients undergoing cardiac surgery represents a challenge to the whole perioperative care team, necessitating comprehensive and individualized plans for surgery and possible factor replacement strategy.¹⁰ This case highlights the challenges in the management of patients with FXI deficiency undergoing cardiac surgery and the need for a multidisciplinary approach. Caution is warranted when using FXI concentrate in this patient population.

Conflicts of Interest

The authors declare no conflicts of interest.

References

- 1 Fitzsimons MG, Leaf RK, Mack J, et al. Perioperative management of a redo aortic root replacement in a patient with severe factor XI deficiency. *J Card Surg* 2018;33:86–9.
- 2 Puy C, Rigg RA, McCarty OJT. The hemostatic role of factor XI. *Thromb Res* 2016;141S2:S8–11.
- 3 Chai-Adisaksopha C, Rattanathamthee T, Drakulic M, et al. Perioperative management for congenital factor xi deficiency; a systematic review. *Blood* 2016;128:3796.
- 4 Gay ND, Azar S, Salomon O, et al. Management of severe factor XI deficiency in cardiac surgery: A case report and review of the literature. *Haemophilia* 2017;23(6):512–4.
- 5 Bauduer F. Uneventful long-term anticoagulation with fluindione in a patient with severe factor XI deficiency. *Haemophilia* 2015;21:e72–3.
- 6 Batty P, Honke A, Bowles L, et al. Ongoing risk of thrombosis with factor XI concentrate: 5 years experience in two centres. *Haemophilia* 2015;21:490–5.
- 7 Petroulaki A, Lazopoulos G, Chaniotaki F, et al. Factor XI deficiency and aortic valve replacement: Perioperative management. *Asian Cardiovasc Thorac Ann* 2017;25:450–2.
- 8 Richards EM, Makris MM, Cooper P, et al. In vivo coagulation activation following infusion of highly purified factor XI concentrate. *Br J Haematol* 1997;96:293–7.
- 9 Mannucci PM, Bauer KAS, Santagostino E, et al. Activation of the coagulation cascade after infusion of a factor XI concentrate in congenitally deficient patients. *Blood* 1994;84:1314–9.
- 10 Strauss ER, Mazzeffi MA, Williams B, et al. Perioperative management of rare coagulation factor deficiency states in cardiac surgery. *Br J Anaesth* 2017;119:354–68.